

**Skin development in Atlantic salmon
(*Salmo salar*) post-smolts reared in
freshwater or low strength seawater
and effect on susceptibility to
*Tenacibaculum finnmarkense***



Thesis for the degree Master of Science in Aquamedicine

Department of Biological Sciences

UNIVERSITY OF BERGEN

June 2020

© Marte Fredriksen

University of Bergen, 2020

Acknowledgments

The work presented in this thesis for the degree Master of Science in Aquamedicine is conducted at the University in Bergen, Department of Biological Sciences (BIO), and at the Fish Health Research Group at Nofima, Ås. The study is financed by the Norwegian Seafood Research Fund (FHF) and Cermaq Group, and is part of the project “Limit the effect of Tenacibaculosis in Norwegian salmon farming” (project no. 901433) which addresses the prioritized task: “*Increasing knowledge that can help to limit the outbreak of disease in salmonids caused by the Tenacibaculum bacterium*”. The project is a cooperation between the University of Bergen, ILAB (Industrial and Aquatic Laboratory), Nofima, Cermaq Group, and Marin Helse.

Firstly, I would like to thank my supervisors. Thanks to Are Nylund for the facilitation of this master project, and for the guidance along the way. A sincere thanks to Christian René Karlsen for the involvement and engagement in this master project, for the sharing of knowledge and for giving me thorough feedback throughout this process. Secondly, thanks to Sverre Bang Småge in Cermaq for arranging challenge trials and samplings, and for answering questions along the way.

I would also like to thank the people at Nofima, Ås. Thanks to Lene Sveen and Marianne Helén Selander Hansen for teaching me the necessary laboratory techniques in order for me to do the work in this master thesis. A special thanks to Lene Sveen for the engagement, and the discussions and guidance throughout this thesis. Thanks to Gerrit Timmerhaus for help in analyzing materials. And also, thanks to all the people who made me feel welcomed during my stay at Nofima.

Finally, I would like to thank Kristense Solheim for always being available for discussions, and for the collaboration, support, and encouragement during the past year. Thanks to Petter for endless support and for all the dinners that were ready at the table. And also, thanks to my fellow students and friends at the University of Bergen for the great times we have had during these five years.

Marte Fredriksen, June 2020

Abstract

Ulcer development caused by bacterial infections in the sea is a large problem in the Norwegian salmon farming industry, leading to increased mortalities, reduced fish welfare, down-classification at harvest, and increased use of antibacterial drugs. In recent years, infection with *Tenacibaculum finnmarkense* has been an increasing problem. Tenacibaculosis affects farmed salmon of all sizes but especially post-smolts in the first period after sea transfer. The transition of smolts from land-based facilities to seawater net-pens is challenging as the period after smoltification shows signs of temporary immune suppression. This study investigated if rearing conditions affect the barrier functions of Atlantic salmon (*Salmo salar*) skin and susceptibility of infection with *T. finnmarkense*. The goal was to histologically characterize any structural differences in the skin of fish reared at two salinities that could explain any differences in mortalities and the prevalence of the bacterium within challenged groups. This study showed that the skin is affected by the degree of salinity in the post-smolt phase. The skin of fish reared in freshwater (0 ppt) developed differently compared to the fish reared in low strength seawater (26 ppt). Also, the skin surface of freshwater fish was poorer compared to brackish water fish three days post challenge, suggesting skin of fish without seawater adaptation to be more affected when transferred to seawater. Results from gene expression analysis indicate significantly stress in the outer skin layers, and the presence of *T. finnmarkense* in the skin is reflected in the up-regulation of several immune-related genes. Although differences between rearing conditions were confirmed in this study, no structural differences that would explain why adapting smolts to seawater before sea transfer seem beneficial were identified. Therefore, more research on this topic is needed.

Table of contents

Acknowledgments	3
1 Introduction	8
1.1 Norwegian salmon farming	8
1.2 Skin disorders by infectious agents	9
1.3 Tenacibaculosis and <i>Tenacibaculum</i> spp.	10
1.3.1. Tenacibaculosis in Northern Norway by <i>Tenacibaculum finnmarkense</i>	12
1.4 Fish skin.....	13
1.5 Aim of study	18
2 Material and methods	19
2.1 Fish husbandry.....	19
2.2 Challenge material	19
2.3 Experiment design	20
2.3.1 Pre-challenge	22
2.3.2 Trial 1: Challenge 1F.....	22
2.3.3 Trial 2: Challenge 2F & 2LSS.....	23
2.3.4 Trial 3: Challenge 3F & 3LSS.....	23
2.4 Sampling	23
2.5 Histological analysis.....	24
2.5.1 Preparations of samples.....	24
2.5.2 Manual measurements and morphology of jaw 0-samples	26
2.5.3 Digital measurements of ventral and dorsal 0-samples.....	27
2.5.4 Morphology and histopathological changes of 3 dpc-samples	27
2.5.5 Immunohistochemistry	28
2.6 Preparations of RNA for gene expression analysis	28
2.6.1 Separation of skin samples into dermis and epidermis	28
2.6.2 Cellular disruption and RNA extraction.....	29

2.6.3 RNA quality	30
2.7 Microarray	30
2.8 Statistical analysis.....	30
3 Results	32
3.1 Sampling.....	32
3.1.1 0-sampling	32
3.1.2 3 dpc-sampling	34
3.2 Histological analyses	36
3.2.1 Manual measurements of jaw skin-samples.....	36
3.2.2 Digital measurements of ventral and vent skin-samples (Aiforia®).....	42
3.2.3 Description of histopathological changes.....	44
3.2.4 Immunohistochemistry	49
3.3 Gene expression.....	55
4 Discussion	56
4.1 Salmon smolts stocked at higher salinity have lower mortality when challenged with <i>T. finnmarkense</i>	56
4.2 Weight and condition factor	58
4.3 Salinity and growth effects on skin morphology	58
4.4 Pathological findings	59
4.5 Histopathological changes by <i>T. finnmarkense</i>	59
4.6 Immunohistochemistry and gene expression provide insights into the pathogenesis of <i>T. finnmarkense</i>	62
4.7 Methodical limitations	63
4.7.1 Histology	63
4.7.2 Experimental setup	64
5 Conclusion and future perspectives.....	65
References	67
Appendix	75

Appendix 1 – Scoring schemes	75
Appendix 2 – Challenge experiment	78
Appendix 3 – Morphology and histological measurements of jaw 0-samples.....	80
Appendix 4 – Morphology and histological measurements of jaw 3 dpc-samples	82
Appendix 5 – Immunohistochemistry	88
Appendix 6 – Gene expression	89

1 Introduction

1.1 Norwegian salmon farming

Today, Norway is the world's largest producer of Atlantic salmon (*Salmo salar*), with 1.2 million tons salmon produced in 2018 with a total first-hand value of 60 billion NOK (Statistics-Norway, 2019). The Norwegian industry has come a long way from the start of salmon fish farming in the 1970' to this day, though not without challenges. The introduction of large net-pen systems increased water quality but also allowed increased production at each site. Fish reared in open environments will be in continuous contact with infectious agents like viruses, bacteria, fungi, and protozoan, and the risk and impact of infectious diseases are further increased in intensive rearing of fish. In the winter of 1979-1980, several Norwegian fish farms suffered from outbreaks of cold-water vibriosis (*Aliivibrio salmonicida*), followed by outbreaks of vibriosis (*Vibrio (Listonella) anguillarum*) and furunculosis (*Aeromonas salmonicida* subsp. *salmonicida*) in the early 1990'. The diseases led to mass mortalities and extensive use of antibiotics, and it was not until the introduction of the oil-adjuvant injection vaccine in 1992 that the industry managed to control the diseases (Gudding, 2010; Markestad & Grave, 1997; Sommerset, Krossøy, Biering, & Frost, 2005). As a result of the oil-adjuvant injection vaccine, there was a substantial decline in levels of antibacterial drugs in Norwegian fish farming. Today, these bacterial diseases are controlled by vaccines in combination with improved husbandry and management practices, and the consumption of antibacterial drugs in the Norwegian aquaculture industry is regarded as low (Sommerset et al., 2020). In 2016 the level was at its lowest since 1981. Levels have since increased, due to several outbreaks of yersinosis (*Yersinia ruckeri*) affecting large fish (Grave & Helgesen, 2018) and more frequent treatment of cleaner fish (lumpfish, *Cyclopterus lumpus*) (Hjeltnes, Bang-Jensen, Bornø, Haukaas, & Walde, 2019).

Mortalities associated with ulcer development by infectious agents have been shown to be the main cause of death (Aunsmo et al., 2008). In a relatively recent survey from 2015, the proportion of sea-farmed salmon dying due to ulcer development (of all causes) in Norway was conservatively estimated to be between 1.1 and 2.5 % annually (Takle et al., 2015). Besides, 0.7 to 3.8 % is down-classified at harvest due to reduced market quality. Application of these figures to the NOK 60 billion value of salmon produced in 2018 suggests that losses due to ulcer development currently cost the Norwegian aquaculture industry between 0.67 and 1.54

billion NOK¹ annually. In addition to significant financial losses, ulceration contributes to a negative reputation of the industry for consumers that have a growing awareness of animal rights, health, and aquaculture sustainability.

Skin disorders are common in fish farming and ulcerative diseases in salmon production in Norway need to be addressed (Hjeltnes et al., 2019). For bacterial ulcerative skin diseases, there is no vaccine on the market today that provide full protection, and as a result, these diseases are difficult to control. Among these are “winter ulcer disease” associated with *Moritella viscosa* and tenacibaculosis associated with *Tenacibaculum* spp., both of which are of high significance to the industry regarding fish welfare, economic losses and use of antibacterial drugs. The commercially available vaccines containing *M. viscosa*-components only includes the “typical” genotype of *M. viscosa* and is shown to provide different levels of protection (Karlsen, Thorarinsson, Wallace, Salenius, & Midtlyng, 2017). Also, the whole-cell inactivated vaccine using *Tenacibaculum finnmarkense* (strain HFJ^T) did not provide protection against experimentally induced tenacibaculosis (Småge et al., 2018). Consequently, these diseases are considered the main bacteriological problem in the industry today (Småge, 2018). This corresponds well with the results from a recent survey conducted by The Norwegian Veterinary Institute (Sommerset et al., 2020), where ulcer development is rated of high importance in sea-pen farming of salmonid fish among fish health workers and The Norwegian Food Safety Authority.

1.2 Skin disorders by infectious agents

The etiology of skin disorders or ulceration is complex. Mechanical injuries, environmental factors, nutrition, and infectious agents are likely central factors (Takle et al., 2015). One of the biggest problems in the Norwegian salmon farming industry is infection with salmon lice (*Lepeophtheirus salmonis*). Not only is the parasite inflicting substantial costs to the industry and challenging the environment – it is also a big contributor to ulcer development. The salmon lice cause both direct and indirect ulcer development. Firstly, salmon lice feeding on mucus and skin causes rupture of the skin barriers and can alone cause severe skin damage. Secondly, handling of the fish related to de-lousing operations is shown to cause mechanical skin damages including loss of scales (Erikson, Solvang, Schei, Ag, & Aalberg, 2018). Outbreaks of ulcerative diseases often correlate with de-lousing operations and other treatments of the fish

¹ 1.1 and 2.5 % of 60 billion NOK = 0.67 and 1.54 billion NOK.

that cause handling and stress (Sommerset et al., 2020). Considering scales are covered with a thin layer of skin cells (epidermal keratocytes) and mucous cells (Kryvi & Poppe, 2016), loss of scales is per definition a small ulcer. Skin abrasions can allow bacteria to establish an infection (Bornø et al., 2011; Småge, Brevik, et al., 2016).

“Winter ulcer disease” is caused by *M. viscosa* (Benediktsdóttir, Verdonck, Spröer, Helgason, & Swings, 2000), a bacterium that is pathogenic to a wide range of species reared in marine waters all over the world (Lunder, Evensen, Holstad, & Håstein, 1995). However, outbreaks of disease are primarily reported from salmonid fish. Little is known of *M. viscosa* virulence, but it is suggested extracellular products (ECPs) are cytotoxic to fish cells and therefore lethal to Atlantic salmon (Bjornsdottir, Gudmundsdottir, & Gudmundsdottir, 2011). Different *M. viscosa* strains were discovered to show host-specific virulence (Karlsen, Ellingsen, et al., 2014), and it is anticipated that environmental factors influence the virulence potential. It is further suggested that the status of skin health is important for the susceptibility to infections (Karlsen, Sørnum, Willassen, & Åsbakk, 2012). Current prophylactics are to avoid management that may result in injuries predisposing to ulcers, vaccination (all Norwegian farmed salmon are vaccinated against *M. viscosa*), and removal of infected fish. However, the etiology of outbreaks is complex as *Aliivibrio wodanis* and *Tenacibaculum* spp. are among the numerous bacterial species recurrently reported isolated from winter-ulcer outbreaks (Olsen et al., 2011). *A. wodanis* seems to have an antagonistic effect on *M. viscosa* infection (Hjerde et al., 2015). The bacterium is shown to adhere to the fish cells, causing them to vacuolate, round up and detach from the surface as well as rearrange actin filaments in vitro (Karlsen, Vanberg, Mikkelsen, & Sørnum, 2014). *Tenacibaculum* spp. has been suggested to be an important factor in the pathogenesis of the “winter ulcer disease” (Olsen et al., 2011). Determining which species are implicated directly in disease, which are present as opportunists and which are simply commensals is challenging.

1.3 Tenacibaculosis and *Tenacibaculum* spp.

Tenacibaculosis is an ulcerative disease caused by *Tenacibaculum* spp. and is characterized by scale loss, frayed fins, fin rot, skin lesions and ulcers and mouth erosions (Bruno, Noguera, & Poppe, 2013; Toranzo, Magariños, & Romalde, 2005), with the highest mortality in fish recently transferred into seawater (Småge et al., 2017). Tenacibaculosis was first described in 1977 (Masumura & Wakabayashi, 1977). The genus *Tenacibaculum* was described several years later in 2001 (Suzuki, Nakagawa, Harayama, & Yamamoto, 2001), and today the genus

comprises several species pathogenic to fish (Hansen, Bergh, Michaelsen, & Knappskog, 1992; López et al., 2009; Pineiro-Vidal, Carballas, Gomez-Barreiro, Riaza, & Santos, 2008; Piñeiro-Vidal, Gijón, Zarza, & Santos, 2012; Pineiro-Vidal, Riaza, & Santos, 2008; Wakabayashi, Hikida, & Masumura, 1986). The genus belongs to the family Flavobacteriaceae (Bernardet et al., 1996; McBride, 2014), phylum Bacteroidetes, and clade *Tenacibaculum-Polaribacter*. Isolated *Tenacibaculum* spp. strains from Atlantic salmon are Gram-negative aerobic long rods that grow as yellow-pigmented colonies on marine agar. *Tenacibaculum* spp. are isolated from marine organisms such as fish, jellyfish, algae, and sponges (Avendaño-Herrera, Toranzo, & Magariños, 2006; Ferguson et al., 2010). During 2015 outbreaks of tenacibaculosis in Finnmark, Norway, the link between jellyfish and tenacibaculosis outbreaks were investigated. The study concluded that the jellyfish identified as *Dipleurostoma typicum* most likely are not a vector for *Tenacibaculum* spp., but is thought to cause direct damage to the skin by ejecting stinging nematocysts and thereby allowing an entry point for bacteria (Småge et al., 2017).

Three species of *Tenacibaculum* spp. are associated with the ulcerative disease tenacibaculosis: *Tenacibaculum maritimum*, *Tenacibaculum dicentrarchi*, and *T. finnmarkense*. *T. maritimum* is the most studied bacterium (Suzuki et al., 2001; Wakabayashi et al., 1986) and is associated with disease from a large range of wild and farmed fish species all over the world, including rainbow trout (*Oncorhynchus mykiss*) and Atlantic salmon from Europe, North America and Australia (Avendaño-Herrera et al., 2006; Bruno et al., 2013; Frisch, 2018; Toranzo et al., 2005). Recently it was reported for the first time in Norwegian farmed Atlantic salmon, using a newly developed assay for *T. maritimum* (PHARMAQ-Analytiq, 2017). Also, the bacterium has been isolated from diseased lumpfish used as cleaner fish in Norway (Småge, Frisch, Brevik, Watanabe, & Nylund, 2016). Worth mentioning is that *T. maritimum* is associated with tenacibaculosis in most parts of the world. However, in the Pacific North, the same bacteria cause a different clinical presentation, named mouthrot (Frisch, Småge, Vallestad, et al., 2018). Mouthrot is characterized by yellow plaques in the mouth as the only external clinical sign, with little or no clinical signs internally, and primarily affects smolts recently transferred into saltwater (Frelier, 1994). Thus, the same bacterium is associated with two different types of clinical presentations (Frisch, 2018). The different clinical presentation of mouthrot and tenacibaculosis observed may be due to different factors at different geographical locations, such as genetic differences between the strains, host factors, and environmental conditions (Frisch, 2018), but this is not yet certain. A possibility is that the fish needs a stressor to develop the disease in Canada, similar to what has been reported in Norway (Småge et al., 2017).

T. dicentrarchi was described in 2012, isolated from diseased European sea bass (*Dicentrarchus labrax*) in Spain (Piñeiro-Vidal et al., 2012) and have later been reported from Atlantic cod (*Gadus morhua*) in Norway in 2009-2010 (Habib et al., 2014) and from Atlantic salmon farms in Chile in 2010 and 2014 (Avendaño-Herrera et al., 2016). The bacterium was for the first time reported from Atlantic salmon in Norway in 2019, isolated from an outbreak of diseased Atlantic salmon (Klakegg, Abayneh, Fauske, Fülberth, & Sørum, 2019).

1.3.1. Tenacibaculosis in Northern Norway by *Tenacibaculum finnmarkense*

A study from 2011 (Olsen et al.) investigated skin ulcers from 18 different field outbreaks of winter ulcer disease in Norway from two different periods, 1996 and 2004-2005. *Tenacibaculum* strains were detected in 70 % of ulcers from all outbreaks. Although the bacterium was easily detected histologically, it was difficult to grow the bacterium, suggesting *Tenacibaculum* spp. may have been underdiagnosed previously. Norwegian isolates of *Tenacibaculum* are genotypically diverse but are phylogenetically related to *T. dicentrarchi* isolated from European sea bass (Habib et al., 2014). Due to the continuation of the ulcerative problem in Atlantic salmon farming, research on *Tenacibaculum* in Norway has gained more focus in recent years.

T. finnmarkense was first described in 2016 from an outbreak of an ulcerative disease from Atlantic salmon reared in seawater net pens in Finnmark, Norway (Småge, Brevik, et al., 2016). Genetic, phenotypic, and chemotaxonomic analysis indicated that the isolated strain HFJ^T should be classified as a novel species in the genus *Tenacibaculum*, for which the name *Tenacibaculum finnmarkense* was proposed. Bath challenges showed that *T. finnmarkense* is the causative agent of tenacibaculosis in Northern Norway reproducing jaw erosions, frayed fins, and skin lesions, which are all classical signs of tenacibaculosis (Småge et al., 2018). Cohabitation experiment showed that *T. finnmarkense* does not appear to spread horizontally from fish to fish (Småge et al., 2018). The results from the bath challenge experiment reflect the acute disease progression observed in field outbreaks that often occur within after seawater transfer.

The bacterium is rarely isolated from the kidney. Although the bacterium is not systemic, *T. finnmarkense* can induce disease by effectively colonize skin surfaces of fish. There are so far no described virulence mechanisms in Norwegian isolates of *Tenacibaculum*. In the experiment of this master thesis, the *T. finnmarkense* strain HFJ^T previously shown to experimentally induce tenacibaculosis in Atlantic salmon (Småge et al., 2018) was used.

1.4 Fish skin

To understand how skin diseases work, a better understanding of skin structures and their functions is needed. The fish skin is a vital organ with many functions and structural compartments involved in immunological defense, osmoregulation, respiration, excretion, sensing, and pigmentation. The skin, in addition to the gills and the gastrointestinal tract, is covered with epithelium and make up the surface and the physical barrier between the internal and external environment (Esteban, 2012). The epithelium is covered with mucus, and together they are the first line of defense for invading pathogens (Benhamed, Guardiola, Mars, & Esteban, 2014). The structure and functions of fish skin vary depending on species, life cycle, and area of the body (Kryvi & Poppe, 2016; Pittman et al., 2013; Roberts & Ellis, 2012). However, some features are common for most skin types (Figure 1, Figure 2). In general, the fish skin consists of an outer epidermis and surface-covering mucus, and an underlying dermis and hypodermis. The mucus covering the epithelium is involved in an array of immunological functions and is referred to as mucosa-associated lymphoid tissue (MALT). MALT is further divided in gut-associated lymphoid tissue (GALT), skin-associated lymphoid tissue (SALT), gills-associated lymphoid tissue (GIALT) depending on location (Esteban, 2012). In general, when a pathogen adheres to the skin, the response is to increase mucus production. Fish slough mucus, and as a consequence, pathogens adhering to skin mucus will be removed (Esteban, 2012).

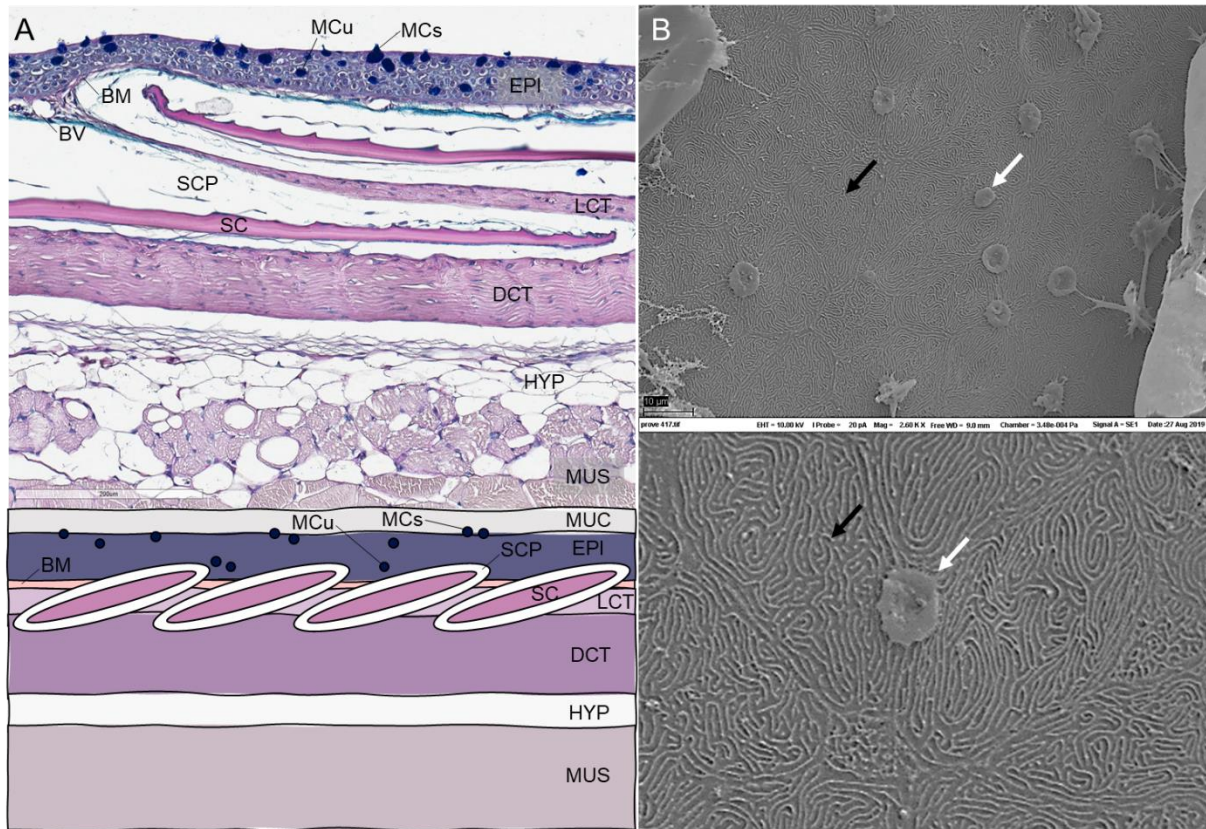


Figure 1. Atlantic salmon skin. **A.** Histological section (Alcian blue – Periodic Acid Schiff, AB-PAS) and schematic figure of scaled skin of Atlantic salmon showing normal anatomy, with mucus (MUC), surface mucous cells (MCs), underlying mucous cells (MCu), the epidermis (EPI), basal membrane (BM), scale pockets (SCP), scales (SC), loose connective tissue (LCT), dense connective tissue (DCT), hypodermis (HYP), muscle (MUS) and blood vessels (BV). LCT and DCT make up the dermis layer. Only blue mucous cells are pictured. **B.** Scanning electron microscopy (SEM) of surface epithelial cells (keratocytes) with micro ridges (black arrows) and intermediate mucous cells (white arrows). Histology and SEM samples are from this current study.

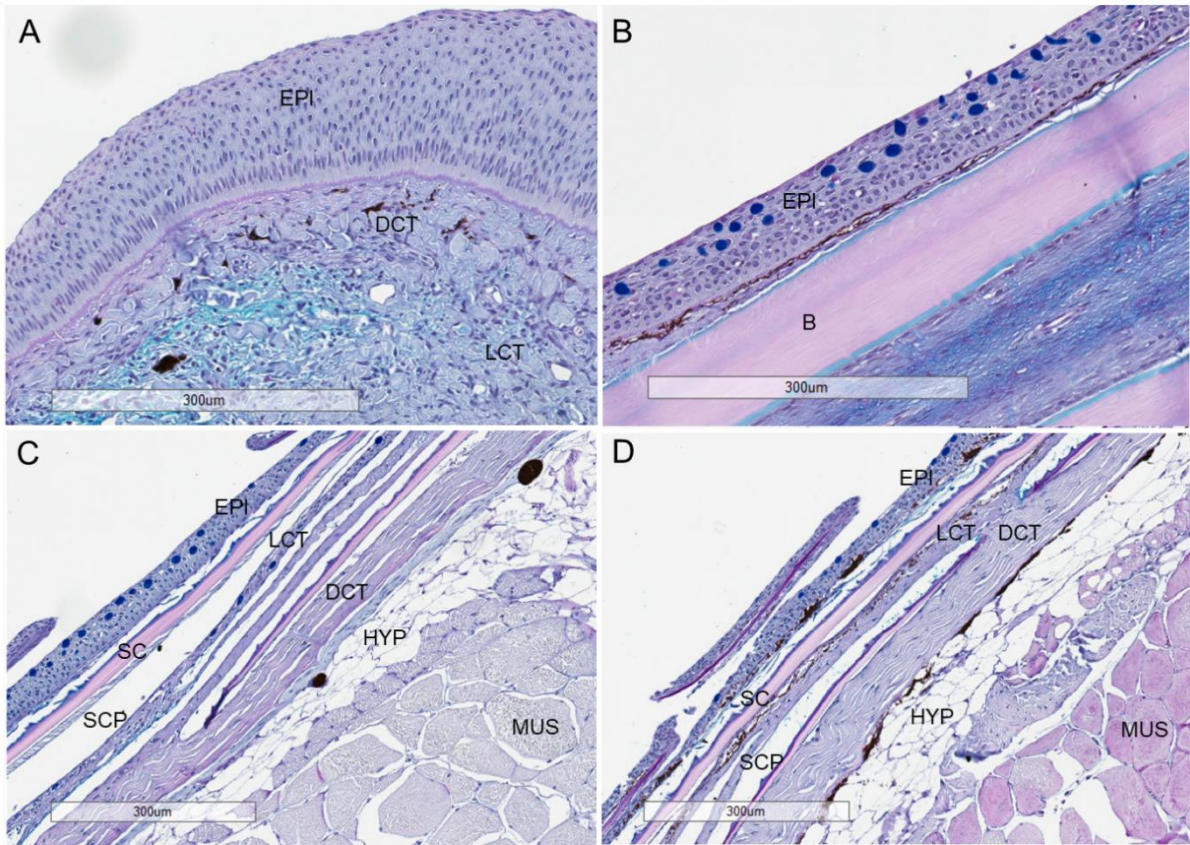


Figure 2. Representative histological sections (Alcian blue – Periodic Acid Schiff, AB-PAS) of Atlantic salmon skin, showing normal skin anatomy at four different sites of the fish. **A.** Tip of the lower jaw, showing epidermis (EPI), dense connective tissue (DCT), and loose connective tissue (LCT), and pigment cells in clusters. **B.** Longitudinal section of the base tail fin, with the epidermis and bone (B). Pigmentation is spread out at the base of the epidermis. **C - D.** Ventral and dorsal side, respectively, showing the epidermis, loose and dense connective tissue, scales (SC), scale pockets (SCP), hypodermis (HYP), and muscle (MUS). Pigment cells in clusters in the ventral side while it is spread out on the dorsal side. All samples are from this current study.

The epidermis

The outermost layer of the fish skin is the epidermis, consisting of an avascular stratified epithelium. The cells of the epidermis are called keratocytes. These cells are linked together with numerous strong bonds of desmosomes and the intermediate filament cytoskeleton. The bonds form a network called the desmosome-intermediate filament complex (DIFC), which glue adjacent cells together to an unbroken sheet that provides great mechanical strength and integrity (Garrod & Chidgey, 2008; Kryvi & Poppe, 2016). The skin is subjected to a substantial amount of mechanical stress. Thus, it is important that cells are strongly held together. The thickness of the epidermis varies between species and between different sites of the fish body (Kryvi & Poppe, 2016). In salmon, the epithelium is thickest in the scaleless parts of the fish like the head region and fins (Pittman et al., 2013) and the jaw (Figure 2).

The epidermis can be divided into three layers, of which all layers are viable (Kryvi & Poppe, 2016). The outermost layer is the *stratum superficiale*. This layer consists of flattened keratocytes with surface micro ridges (Figure 1 B). The micro ridges provide a larger surface and function to adhere mucus (Kryvi & Poppe, 2016; Quilhac & Sire, 1999). In the case of skin injury, the keratocytes can rapidly migrate to re-epithelialize and close the wounds (Sveen, Karlsen, & Ytteborg, 2020). The intermediate layer is called the *stratum spinosus* and consists of rounder undifferentiated epidermal progenitor cells. The basal layer is the *stratum basale*, which consists of cubical to tall cells, in addition to a protein layer that makes up the basement membrane. The function of the basement membrane is to anchor the epidermis to the dermis.

In addition to keratocytes, the epidermis always has mucus-secreting cells (mucous cells), and in some cases pigment cells and different leucocytes, i.e. macrophages and eosinophilic granular cells. Some species have club cells and sacciform cells (Kryvi & Poppe, 2016). The density of mucus-producing cells in the epidermis is dependent on the body site, with the highest density on the dorsal side of the fish and the lowest in the head region (Pittman et al., 2013) (Figure 2). The mucous cells produce mucins, which are large and complex glycoproteins that make up the mucus layer (Shephard, 1994). There are different types of mucins; acidic, neutral, and a combination of the two. The acidic mucins are characterized by the presence of sialic acid or sulfated monosaccharides and a blue color when stained with Alcian blue – Periodic Acid Schiff (AB-PAS) (Fletcher, Jones, & Reid, 1976), while the neutral mucins stain bright purple or pink. The content of the mucous cell is released to the surface (Figure 1 B), swells when in contact with water, and is distributed on the surface of the skin (Kryvi & Poppe, 2016). In addition to mucins, the mucus layer consists of immunological components, sialic

acid, antibodies, enzymes, and lysosomes (Esteban, 2012), making this an important site for antibacterial activity (Svendsen & Bøggwald, 1997).

The dermis

The dermis is a vascular tissue consisting of collagen-producing fibroblasts. The dermis consists of two main components, loose connective tissue, and dense connective tissue (Figure 1 A, Figure 2), also referred to as *stratum spongiosum* and *stratum compactum*, respectively. Dense connective tissue is more defined in scaled skin than in unscaled skin for example in the head region and fins of Atlantic salmon (Elliott, 2011) (Figure 2). The loose connective tissue consists of unorganized collagen fibers, fibroblasts, pigment cells, nerves, blood vessels, in addition to scales. The scales (cycloid scales in salmonids) are located inside scale pockets, made up of the scale pocket-lining (Sire, 1989), and covered with a layer of epidermis (Figure 1 A, Figure 2 C – D). In contrast to loose connective tissue, dense connective tissue consists of highly organized collagen fibers in alternating directions, and only fibroblasts additionally (Figure 1 A, Figure 2 C – D). The main function of the dense connective tissue is to ensure strength and flexibility (Kryvi & Poppe, 2016).

The hypodermis

The hypodermis consists of loosely organized collagen fibers, adipocytes (fat storage cells), and pigment cells (Figure 1 A, Figure 2 C – D). The thin layer separating the hypodermis from the dermis is called the dermal endothelium (Kryvi & Poppe, 2016).

1.5 Aim of study

Susceptibility to *Tenacibaculum* infection increase during the first time-period after seawater transfer. During this stage, the skin immune system is suppressed, and Atlantic salmon could experience increased susceptibility to infectious agents and the risk of diseases. This study aimed to investigate if rearing Atlantic salmon post-smolt in two different water qualities over time affected the susceptibility of *Tenacibaculum finnmarkense* after transmission to seawater.

The main aim will be achieved by the fulfillment of the following subgoals:

- Characterizing the skin structurally by its histological appearance for salmon kept at two different water qualities after smoltification.
- Characterize histopathological changes in the skin after *Tenacibaculum finnmarkense* challenge for smoltified salmon kept in freshwater or low strength seawater.

2 Material and methods

The work presented in this thesis use material from a challenge experiment carried out at the Industrial and Aquatic Laboratory (ILAB) in Bergen, Norway in the period from February 19th, 2019 to July 30th, 2019. The experimental model is used to study the development of the skin tissue in post-smolts reared at two water qualities, freshwater (F) and low strength seawater (LSS) and investigates if the rearing conditions influence susceptibility to *T. finnmarkense*. The two different water qualities and the time before challenge in full-strength seawater represent the different production strategies in Norwegian salmon farming today, where the most common strategy is to transfer the post-smolt from freshwater directly to seawater when smoltified. A separate master thesis (Solheim, 2020) describes the difference in prevalence and infection using real-time RT-PCR (rt qPCR) to identify levels of *T. finnmarkense* between the experimental groups utilizing the same sample material as in this thesis.

2.1 Fish husbandry

Unvaccinated Atlantic salmon smolts (n = 568) were reared in the production facility at ILAB at the University of Bergen. All the fish had the same genetic origin coming from StofnFiskur, Iceland. The fish were evenly distributed to four separate freshwater flow-through tanks measuring 500 L with water at 12 °C. The water flow was adjusted between 3000 and 2000 L/h during the experiment and the oxygen level was monitored. The freshwater in ILAB was from Svartediket, Bergen. Two and two tanks had linked water supply. The fish were fed in excess with automatic feeding using commercial dry feed Nutra Olympic (Skretting, Norway). The fish were monitored twice a day by ILAB staff. The fish were screened by ILAB-staff before the start of the experiment and found negative for *Piscine orthoreovirus*, *Piscine myocarditis virus*, *Infectious pancreatic necrosis virus*, *Infectious salmon anemia virus*, and *Salmonid alphavirus*. The fish were kept on a 12-hour photoperiod, except during and after smoltification, for which fish were kept on a 24-hour photoperiod.

2.2 Challenge material

The bacterial strain used for the challenge was *T. finnmarkense* strain HFJ^T isolated from diseased Atlantic salmon suffering from tenacibaculosis at seawater site in Finnmark, Norway in 2013 (Småge, Brevik, et al., 2016). The strain has previously shown to experimentally induce tenacibaculosis in Atlantic salmon (Småge et al., 2018). Preparation of the challenge material

(batch cultures of *T. finnmarkense*) used in this study was conducted by Solheim (2020) and Cermaq-staff. The stock was made using *T. finnmarkense* strain HFJ^T (passage 5) and marine broth (MB) and incubated at 16 °C with shaking (140 rpm) for 48-52 hours and stored at -80 °C until use. See Solheim (2020) for additional details.

2.3 Experiment design

Three different challenge trials were carried out to test the different variables (environment conditions and smolt size) required to develop the challenge model and test our hypothesis for *T. finnmarkense* infection of Atlantic salmon post-smolts. The experimental trial was approved by the Norwegian Food Safety Authority (Mattilsynet) under the identification code 19450 and was conducted under regulations controlling experiments and procedures in live animals in Norway. For the duration of each challenge trial, the fish were monitored at least twice a day for signs of disease (especially post challenge) and fish with behavioral changes and/or clinical signs like erratic swimming, swimming near the water surface, color changes or severe ulceration were collected, killed and removed from the experiment.

The experiment design is illustrated in Figure 3. After smoltification, the first smolts were transferred from the production facility to the challenge facility for a pre-challenge test to adjust the challenge dosage to be used in the challenges. Remaining smolts were kept on freshwater in the production facility before fish were transferred to the challenge facility for challenge 1F (Trial 1). Remaining smolts in the production facility were divided into two groups, where one group was kept on freshwater while the other group was kept on low strength seawater, both still at 12 °C and 24-hour photoperiod. The fish were held for four weeks at the production facility before the next transmission of smolts to the challenge facility for challenge 2F & 2LSS (Trial 2). Remaining smolts in the production facility were held at their respective water qualities for another four weeks before being transferred to the challenge facility for challenge 3F & 3LSS (Trial 3). For all challenge groups, there were three replicate challenge tanks and one control tank.

Before challenge, the fish were starved for 24 hours and then transferred from the production facility to challenge-tanks in the challenge facility. The challenge tanks measured 150 L with water (the same water quality the fish had in the production facility) at 10 °C and had a flow rate at 300 L/h. The fish were fed in excess with automatic feeding and kept at 24-hour photoperiod. The water temperature was turned down to 8 °C and full-strength seawater was turned on 24 hours before challenge. The fish were starved 48 hours before challenge.

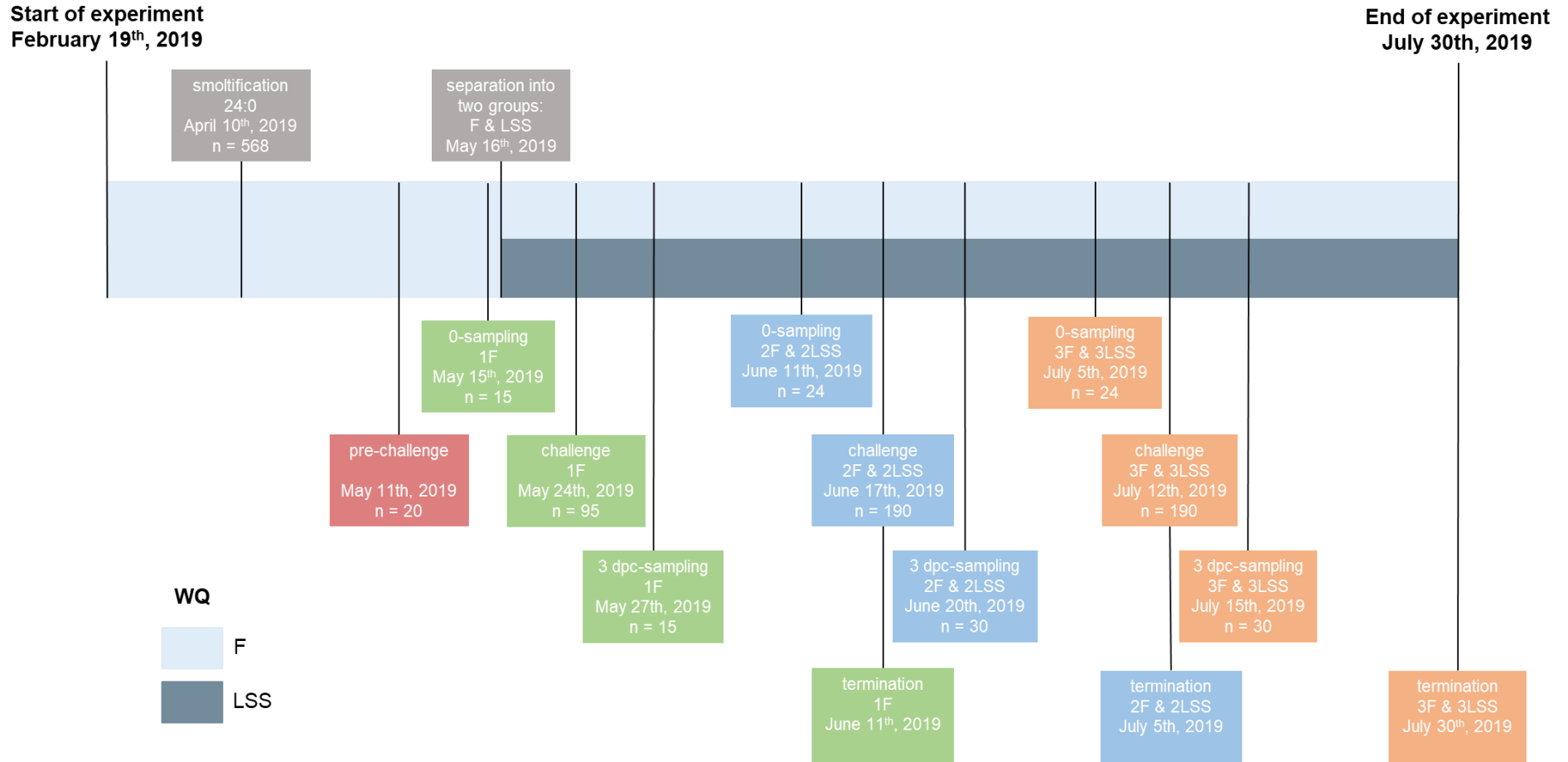


Figure 3. Timeline of the experiment, showing the number of fish (n), the start and the end of the experiment, initiation of smoltification, separation of fish into two groups reared in two different water qualities (WQ), freshwater (F) and low salinity seawater (LSS), pre-challenge (red), challenge, 0-sampling, 3 dpc-sampling (dpc = days post challenge) and termination for Trial 1 (green), 2 (blue) and 3 (orange).

2.3.1 Pre-challenge

To determine the optimal infection dosage of *T. finnmarkense* to be used in the challenge trials, a pre-challenge was conducted. Five fish from each of the four tanks in the production facility was transferred to the challenge facility, where they were acclimated in freshwater tanks at 10 °C for two days before the temperature was turned down to 8 °C and full-strength seawater was turned on 24 hours before challenge. The light regime in the challenge facility was 24 h. The fish were then transferred to separate seawater tubs (34 ppt) measuring 60 L at 8 °C. The water in the tubs was oxygenated using pressure diffuser and supervised. The fish were then challenged with two different dosages, 2.2×10^6 cells/mL (high) and 7.75×10^5 cells/mL (low) of *T. finnmarkense* HFJ^T, ten fish per dosage. The dosage of 200 and 75 mL (high and low, respectively) was added directly in the tubs. The time of infection was two hours before the fish were transferred back to their respective challenge tanks.

2.3.2 Trial 1: Challenge 1F

Challenge 1F aimed to test the susceptibility for *T. finnmarkense* of newly smoltified salmon (n = 95) with an average weight of 71 g² after the transition to seawater. The fish were transferred from the production facility to four separate challenge-tanks measuring 150 L in the challenge facility. Tank 1-3 (n = 23 for each tank) were the challenge tanks while tank 4 (n = 26) was the control tank. The fish were acclimatized in freshwater at 10 °C for two days before the temperature was turned down to 8 °C. Fish were starved 48 hours before challenge. The light in the challenge facility was 24 h. Full-strength seawater (34 ppt) was then turned on 24 hours before the challenge. The fish were then transferred to four separate seawater tubs (34 ppt) measuring 60 L at 8 °C. The water in the tubs was oxygenated using pressure diffuser and supervised. The experimental groups were challenged with the adjusted dosage of *T. finnmarkense* strain HFJ^T of 1.57×10^6 cells/mL. The dosage was determined based on the dosage used in the pre-challenge. The control group was treated the same way as the experimental group, only with an uninoculated growth medium as control. The total amount added directly in the tubs was 200 mL. The time of infection was two hours before the fish were then transferred back to their respective challenge-tanks. The experiment was terminated 19 days post-challenge.

² Average weight provided by ILAB-staff.

2.3.3 Trial 2: Challenge 2F & 2LSS

Challenge 2F & 2LSS aimed to test the susceptibility for *T. finnmarkense* of post-smolts (n = 95 for each group) with an average weight of 105 and 90 g, respectively. The process was the same as for challenge 1F, with the addition of the 2LSS fish which were acclimated in low strength seawater. The experimental groups were challenged using a dose of *T. finnmarkense* strain HFJ^T of 1.69×10^6 cells/mL. The total amount added was 250 mL. The dosage was adjusted from experiment 1F based on the mortality in challenge 1F. The experiment was terminated 19 days post-challenge.

2.3.4 Trial 3: Challenge 3F & 3LSS

Challenge 3F & 3LSS aimed to test the susceptibility for *T. finnmarkense* of post-smolts (n = 95 for each group) with an average weight of 150 and 124 g, respectively. The process for 3F & 3LSS were the same as for 2F and 2LSS, respectively. The experimental groups were challenged with a dose of 1.71×10^6 cells/mL *T. finnmarkense* strain HFJ^T. The total amount added was 280 mL. The experiment was terminated 19 days post-challenge.

2.4 Sampling

Samplings were carried out at ILAB in Bergen, Norway. Fish sampled before challenge from the production facility will hereby be referred to as 0-samples, while fish sampled three days post challenge (1F, 2F & 2LSS, and 3 & 3LSS) from the challenge facility will hereby be referred to as 3 dpc-samples. In total six samplings were conducted in the period between May 15th, 2019, and July 15th, 2019. See Figure 3 for the number of fish sampled.

For all samplings, the following tissues were sampled from each fish: ventral skin, dorsal skin, lower jaw, and caudal fin. Each tissue sample was cut in half – one half for gene transcription analysis and the other half for histology. The fish were transferred from their tanks to buckets where they were euthanized with an overdose of Finquel Vet. (Scan Aqua) and if necessary, a stroke to the head. The fish were then transferred to the laboratory where they were weighed and measured (fork length) before they were scored according to Nofima's fish welfare scoring scheme (Noble et al., 2018). Additional scoring was performed on 3 dpc-samplings, where ulcers were scored according to size and location on the fish (see Appendix 1 for scoring schemes).

Samples were excised from four areas of the fish (left side up) using a scalpel, forceps, and a pair of scissors. Dorsal and ventral skin-samples were excised from the area posterior of the

dorsal and pelvic fins, above and one piece under the lateral line, respectively. The lower jaw and the top of the caudal fin were cut off. Samples for microarray analysis were added in Eppendorf tubes containing RNAlater™ (Invitrogen) and stored in room temperature for 1 day before stored at –20 °C until RNA extraction. The other set of samples for histology were added in 20 ml pots containing 10% buffered formalin (CellStor™ pots, CellPath) and stored at 4 °C until preparations for histology.

For 0-samplings, Solheim (2020) sampled skin and kidney for real-time rt qPCR to screen for known bacterial and parasitic pathogens before challenge, in addition to the second gill arch for SmoltVision to verify smolt status. For 3 dpc-samplings, skin and kidney were sampled for rt qPCR to identify levels of *T. finnmarkense*, in addition to skin samples for histology and scanning electron microscopy (SEM). At the termination of each trial, the fish were weighed and measured, and scored for external welfare indicators.

2.5 Histological analysis

The histological analyses used in this thesis included manual and digital measurements of epidermis thickness and mucous cells of 0-samples, in addition to observation of overall morphology and examination of histopathological changes of 3 dpc-samples. 3 dpc-samples with beginning ulcers or developed ulcers were selected for analysis based on ulcer scoring (Appendix 4).

2.5.1 Preparations of samples

Preparations of dorsal, ventral, and jaw 3 dpc-samples (n = 132) were conducted at Nofima, Ås. Samples were cut and trimmed to the proper size and placed in tissue embedding cassettes (Simport Scientific Inc). Cassettes were then added 10% Titriplex 3 (Merck KGaA) decalcifying solution for softening of scales and bones before sectioning. The pH of the solution was measured and adjusted with drops of NaOH (sodium hydroxide) or drops of HCl (hydrochloric acid) until pH = 7. The ventral and dorsal skin-samples were put in the decalcifying solution for a minimum of 24 hours at room temperature and jaw skin-samples a minimum of 48 hours at 4 °C, followed by 30 minutes in room temperature. The samples were then washed in spring water and transferred to phosphate-buffered saline (PBS) solution. Samples were then dehydrated through a graded series of ethanol using a Tissue processor Leica TP1020 (Leica Microsystems). The following concentrations of ethanol were used: 50% (1 h), 70% (1 h), 96% (1 h), 100% (30 min + 30 min + 30 min), followed by xylene (30 min + 30 min

+ 30 min) and paraffin (1 h + 2 h). Samples were embedded in paraffin using a Paraffin embedding module Leica EG1150 H and a Cold plate Leica EG1150 C (Leica Microsystems) before sections (5 µm) were prepared using a Microtome Leica RM2165 (Leica Microsystems) and a Water bath Leica HI1210 (Leica Microsystems). To ensure a nice and even section when cutting in the tough tissue consisting of scales and bone, an extra durable Leica DB80 LX microtome blade was used. Sections were dried in a heated cupboard at 37 °C overnight or at 60 °C for one hour. Slides were deprived of paraffin through deparaffinization in xylene (5 min + 5 min) and ethanol 100% (5 min + 5 min), 96% (5 min + 5 min), 70% (5 min), and 50% (5 min). Sections (n = 2-3 per sample) and then stained using Leica ST5010 Autostainer XL (Leica Biosystems). To differentiate between acidic and neutral mucous cells, slides were stained with AB-PAS and counterstained with Lilly's hematoxylin (Sigma-Aldrich). The process was as follows: 15 minutes in Alcian Blue (Sigma), pH 2,5 followed by 10 minutes in 1% Periodic Acid (Merck KGaA), 15 minutes in Schiff (Merck), and counterstain for 30 seconds. Staining with hematoxylin-eosin (HE) was done by staining the slides for seven minutes in Lilly's hematoxylin (Sigma-Aldrich), followed by three minutes in 1% Hexamine and three minutes in Erythrosine B (Sigma-Aldrich). Right after staining the sections were covered with a coverslip using a fully automated glass cover slipper Leica CV5030 (Leica Biosystems) and then allowed to air-dry in a fume hood for 1-3 days before microscopy.

Preparations of dorsal, ventral, jaw, and tail fin 0-samples (n = 120) were conducted at the Veterinary Institute in Harstad, Norway. Sections (5 µm) were stained with AB-PAS and sent back to Nofima, Ås for scanning, and microscopy.

All samples were scanned electronically using Aperio CS2 Digital Pathology Slide Scanner (Leica Biosystems). The digital slide images were examined in the program Aperio Image Scope (Leica Biosystems).

2.5.2 Manual measurements and morphology of jaw 0-samples

Jaw 0-samples (n = 30) were analyzed manually using Aperio Image Scope. The jaw samples were defined into three areas: Area 1, Area 2, and Area 3 (Figure 4). This was because the structure of the jaw varied significantly between areas, which could alter the results of the measurements. Each area of the jaw was investigated for overall morphology, measured for epidermis thickness (μm ; six length measurements per area) and area (μm^2), and also the number, placement (surface or underlying) and color (blue or purple) of mucous cells.

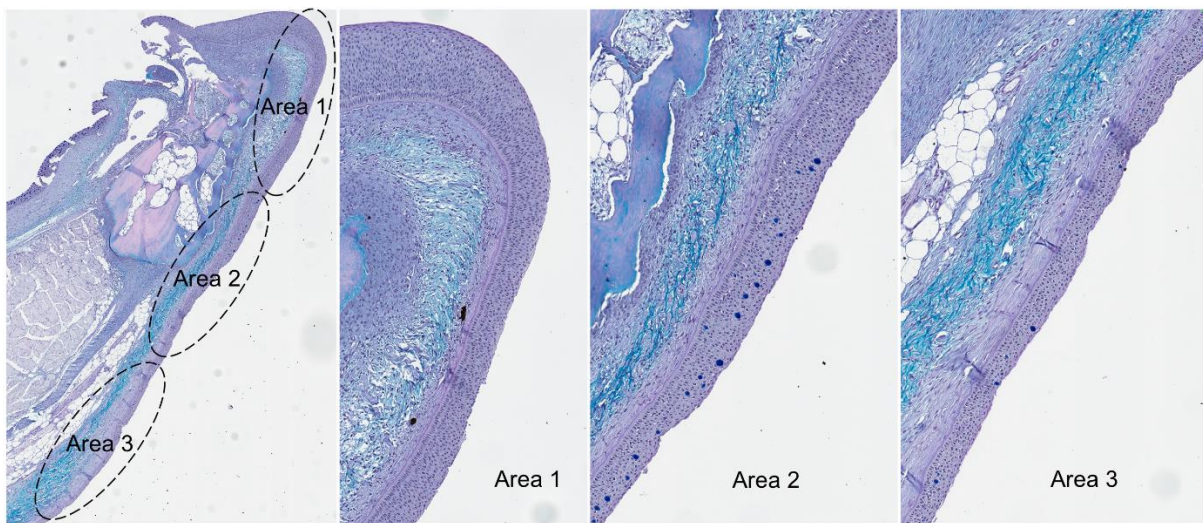


Figure 4. Overview of the different areas of the jaw, Area 1, 2 and 3.

2.5.3 Digital measurements of ventral and dorsal 0-samples

Ventral (n = 30) and dorsal (n = 30) 0-samples were analyzed digitally using artificial intelligence (AI) software Aiforia® (Aiforia Technologies Oy). The software provides deep learning AI or images analysis, based on algorithms. The ventral skin-sample was defined into two areas: ventral and vent (Figure 5), for the same reason as for the jaw. The ventral, vent and dorsal skin-samples were measured for epidermis thickness, and number, placement, and color of mucous cells.

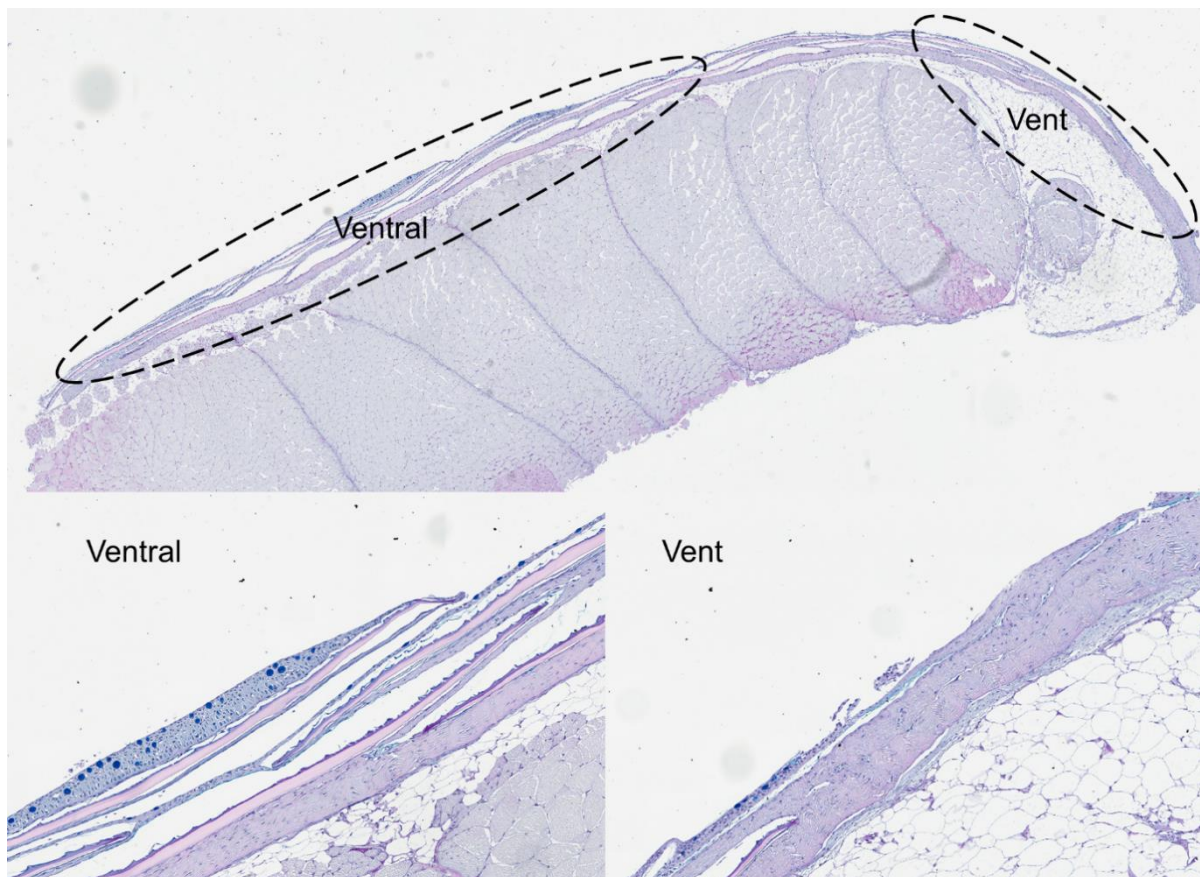


Figure 5. Overview of different areas in ventral skin-samples, showing the ventral area and the vent area.

2.5.4 Morphology and histopathological changes of 3 dpc-samples

Jaw (n = 60), ventral (n = 60) and dorsal (n = 60) 3 dpc-samples were investigated for epidermis morphology, overall morphology, and histopathological changes using Aperio Image Scope. Samples were compared to controls. Groups investigated were 2F & 2LSS and 3F & 3LSS. 1F was excluded due to low mortality and low prevalence of *T. finnmarkense* (Solheim, 2020). For jaw 3 dpc-samples, the epidermis morphology in Area 1, 2, and 3 was scored according to the

degree of damage, ranging from 0-3. Areas with intact epidermis were given score 0, minor damage score 1, moderate damage score 1.5, serious damage score 2, severe damage score 2.5, while areas with destroyed or missing epidermis were given the highest score of 3.

2.5.5 Immunohistochemistry

A selection of ventral and jaw 3 dpc-samples was prepared for immunohistochemistry to verify the presence of *Tenacibaculum* spp. and to locate in what tissue layers of the skin the bacterium was found. Samples (n = 34, including controls) with varying degrees of histopathological changes were sent to the Veterinary Institute in Harstad, Norway for preparations, and sent back to Nofima, Ås for scanning and microscopy. The antibody used was targeting *Tenacibaculum* spp., and as the fish in this experiment were challenged with *T. finnmarkense*, positive samples are assumed to be *T. finnmarkense*.

2.6 Preparations of RNA for gene expression analysis

The preparations for gene expression analysis consisted of two parts. Part one was the separation of the skin-samples into epidermis and dermis. Due to epidermis and dermis being two different tissue layers with different cell types and thus functions, these two tissue layers are thought to have different transcriptional profiles. Part two was the RNA-extraction using the Biomek 4000 (Beckman Coulter) robot and the Agencourt® RNAdvance™ Tissue Kit.

Due to economical limitations, only ventral 3 dpc-samples were selected for microarray analysis. Based on the ulcer scoring (Appendix 2, Appendix 4), most of the ulcers were located on the ventral side, making this area the most interesting tissue to study gene expression.

2.6.1 Separation of skin samples into dermis and epidermis

Qiagen collection microtubes (QIAGEN) were prepared with 400 µl lysis buffer (Beckman Coulter) and two ~3 mm Qiagen beads (QIAGEN) for each sample. The tubes were placed in a 96 well plate. The method for the separation is schematically demonstrated in Figure 6. Each skin sample was separated into epidermis and dermis using forceps and scalpel blades in the following procedure: The sample was taken out of its Eppendorf tube containing RNAlater and placed on a petri dish under the loupe. Six to ten scales were plucked using forceps and the scales were placed down with the epidermis side up. The rest of the sample was put back in the Eppendorf tube to prevent RNA decomposition. The epidermis was carefully scraped off the scales using a scalpel blade and then collected and transferred in the Qiagen collection microtubes containing lysis buffer. The sample was again taken out of its Eppendorf tube and

placed under the loupe. The muscle and the pigmented hypodermis (thin, black layer under the dermis) layer were scraped off using a scalpel blade until only the dermis and scale pockets remained. A small piece (2x2 mm) of the dermis with scale pockets was then transferred in the next Qiagen collection tube containing lysis buffer. This was repeated for all ventral skin-samples.

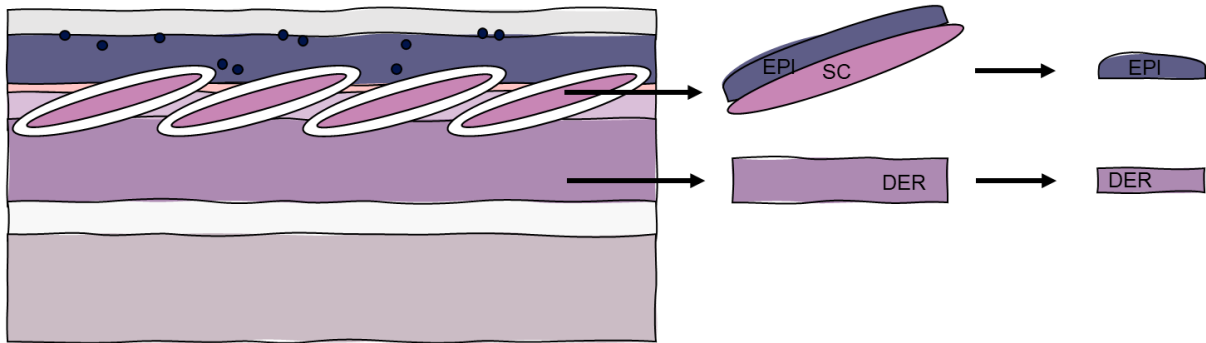


Figure 6. Schematic figure demonstrating the method for separation of skin samples into epidermis (EPI) and dermis (DER). Scales (SC) were plucked and then the epidermis was scraped. The dermis layer was trimmed to the proper size, and both tissues were stored in RNAlater until use.

2.6.2 Cellular disruption and RNA extraction

Qiagen collection tubes containing buffer and sample was used in RNA-isolation protocol. The first step of the RNA extraction was the cellular disruption of epidermal and dermal tissue, to ensure the RNA is available for isolation. For all samples, 20 μ l of Proteinase K (Beckman Coulter) was added (cons 50 mg/ml) to ensure protein digestion, and the tubes were sealed with collection microtube caps (QIAGEN). The plate with samples was then shaken in the FastPrep 96 homogenizer (MP Biomedicals) for 120 seconds with maximum shaking (1800) before it was spun down in a centrifuge and put in the heated cupboard for minimum 30 minutes at 37 $^{\circ}$ C. Samples were then stored at -80 $^{\circ}$ C until RNA extraction.

The extraction of RNA was performed on the Biomek 4000 (Beckman Coulter) robot. The samples were defrosted in the heated cupboard at 37 $^{\circ}$ C and then transferred to a deep well plate. The volume of reagents (70% EtOH, binding solution, DNase, wash buffer) was calculated according to the number of samples and placed in the robot according to the RNA extraction program.

2.6.3 RNA quality

Microarray analysis requires a minimum RNA concentration of 40-50 µl/ml. The purity and integrity of the RNA were analyzed to ensure the samples were not contaminated and that the RNA was not degraded. The RNA concentration and the purity (A260/A280 and A260/A230) of all samples were measured using a NanoDrop™ 8000 Spectrophotometer (ThermoFisher Scientific) and a multichannel pipette. Before measurements, all eight positions on the lower pedestal were blanked with the elution solvent, in this case, nuclease-free water. This to be able to distinguish the absorbance from the blank sample from that of the sample containing RNA. Then, 1 µl sample was loaded onto all eight positions and measurements made. A sample is considered pure when the value for A260/A280 > 2,0 and A260/A230 > 2,2. The integrity of the total RNA for four samples was measured using an Agilent 2100 Bioanalyzer (Agilent Technologies) and the Agilent Small RNA Kit according to the manufacturer's instructions. The quality was assessed by the RNA integrity number (RIN) and samples were considered OK with RIN > 7.5. Total RNA samples were stored at -80 °C until use.

2.7 Microarray

Microarray analysis of the epidermis and dermis ventral skin-samples from different experimental groups were performed using Nofima's 44 k Atlantic salmon oligonucleotide microarray. Microarray, reagents, and equipment were purchased from Agilent Technologies. The microarray contains probes to known protein-coding genes of Atlantic salmon (Salgeno-2). Microarray preparation and analysis were carried out by lab engineers and researchers at the biotechnology lab at Nofima, Department of Fish Health, Ås. In this master thesis, a summary of the response to *T. finnmarensis* infection is presented, including gene transcription patterns of immune, cell, and tissue genes in the epidermis and dermis between study groups.

2.8 Statistical analysis

All graphs were made, and statistical analysis performed in PRISM GraphPad (GraphPad Software) unless stated otherwise. For normally distributed data, a two-way ANOVA was used to test for significant interaction between parameters. For data not distributed normally, a Kruskal-Wallis test was used for the same purpose. Post hoc differences were investigated using either Tukey-Kramer or Dunn's multiple comparison test.

Graphs with the results from Aiforia® and the microarray analysis were made, and statistical analysis was performed by researchers at Nofima. Graphs were slightly modified before presented in this master thesis.

3 Results

3.1 Sampling

Weight (W) in grams and condition factor (CF) and standard deviation (SD) from fish sampled before and three days post-challenge, i.e. 0-sampling and 3 dpc-sampling respectively, are presented in this section.

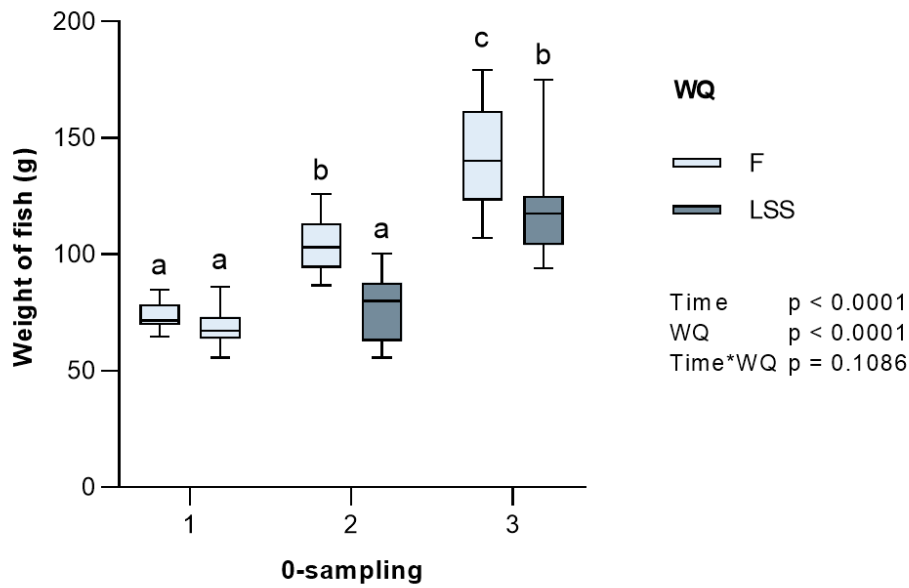
3.1.1 0-sampling

The weight development of fish sampled before challenge is summarized in Table 1. Weight data was significantly different regarding both time ($p < 0.0001$) and water quality ($p < 0.0001$), but not for the interaction between the two ($p = 0.1086$). Figure 7 A shows that weight increased between the three time-points for fish reared in F and between 0-sampling 2 and 3 for LSS. Also, the weight for fish reared in F was higher than that of fish reared in LSS for 0-sampling 2 and 3. CF was significantly different regarding time ($p < 0.0001$) but not water quality ($p = 0.3896$) nor interaction between the two ($p = 0.2740$). CF was higher at 0-sampling 1 compared to 0-sampling 2 and 3 (Figure 7 B).

Table 1. Mean \pm SD weight (g) and condition factor (CF) of Atlantic salmon smolts reared in two different water qualities, freshwater (F) and low strength seawater (LSS), sampled before challenge (i.e. 0-sampling). The time between sample points was four weeks.

0-sampling		Weight	CF
0-sampling 1 n = 15	F	71.5 \pm 7.7	1.23 \pm 0.04
0-sampling 2 n = 24	F	104.7 \pm 14.2	1.12 \pm 0.06
	LSS	77.7 \pm 12.0	1.07 \pm 0.04
0-sampling 3 n = 24	F	141.1 \pm 19.6	1.12 \pm 0.05
	LSS	119.1 \pm 20.9	1.12 \pm 0.08

A



B

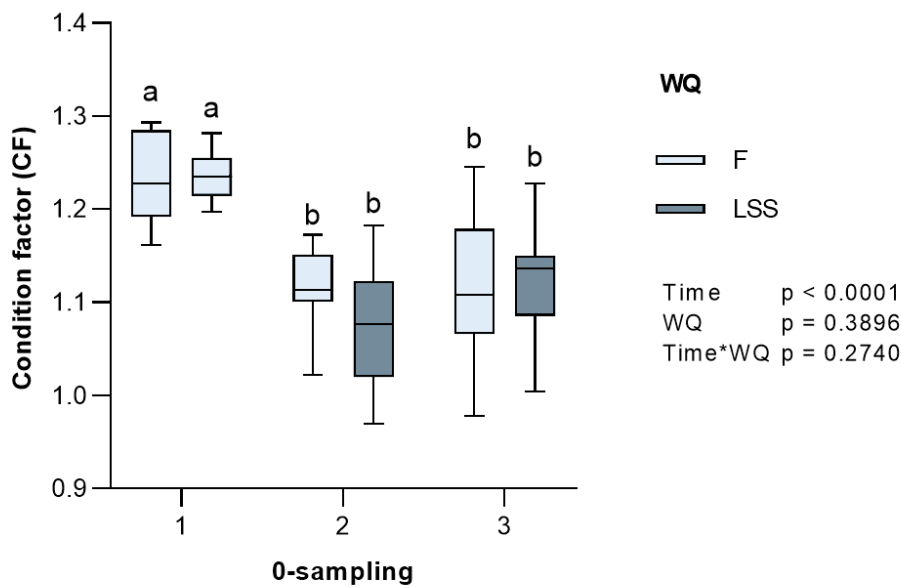


Figure 7. Box plot showing mean \pm SD weight (g) and condition factor (CF) of Atlantic salmon smolts reared in two different water qualities (WQ), freshwater (F), and low strength seawater (LSS). Fish were sampled before challenge ($n = 15, 24,$ and 24 for 0-sampling 1, 2, and 3, respectively). The time between sample points was four weeks. **A.** Weight increased between all samplings for fish reared in F and for sampling 2 and 3 for fish reared in LSS. The weight of F fish was greater than of LSS fish for sampling 2 and 3. **B.** CF was higher at 0-sampling 1 compared to 0-sampling 2 and 3. A comparison of weight and CF between each pair was assessed by a two-way ANOVA. Different letters indicate significant differences between the groups (Tukey-Kramer posthoc test, $p < 0.05$).

3.1.2 3 dpc-sampling

Weight development of challenged and control fish is summarized in Table 2. The weight, but not CF increased over time. Figure 8 A shows the development in weight between challenged and control fish (independent of water quality). Weight was significant different in time ($p < 0.0001$) but not between challenged and control fish ($p = 0.5129$) and neither for the interaction between the two ($p = 0.7486$). Development in CF is shown in Figure 8 B. The effect on condition factor was tested using the Kruskal-Wallis test, indicating no significant difference between time points ($p = 0.1692$).

Table 2. Mean \pm SD weight (g) and condition factor (CF) of Atlantic salmon smolts reared in two different water qualities, freshwater (F) and low strength seawater (LSS), sampled 3 days post challenge (3 dpc). The time between sample points was four weeks.

3 dpc-sampling		Weight	CF
1F	challenge (n = 9)	65.6 \pm 13.1	1.06 \pm 0.04
	control (n = 6)	70.2 \pm 7.6	1.07 \pm 0.04
2F	challenge (n = 9)	98.4 \pm 14.3	1.03 \pm 0.08
	control (n = 6)	101.8 \pm 7.1	1.11 \pm 0.03
2LSS	challenge (n = 9)	98.2 \pm 11.7	1.14 \pm 0.05
	control (n = 6)	92.2 \pm 13.9	1.06 \pm 0.07
3F	challenge (n = 9)	151.1 \pm 21.2	1.07 \pm 0.06
	control (n = 6)	157.8 \pm 18.5	1.15 \pm 0.03
3LSS	challenge (n = 9)	129.0 \pm 16.9	1.13 \pm 0.06
	control (n = 6)	133.7 \pm 25.2	1.12 \pm 0.10

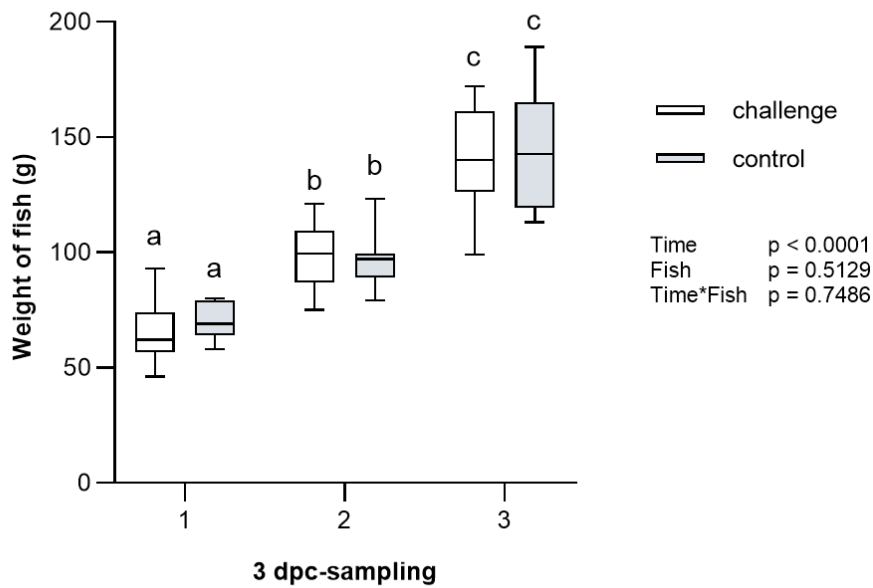
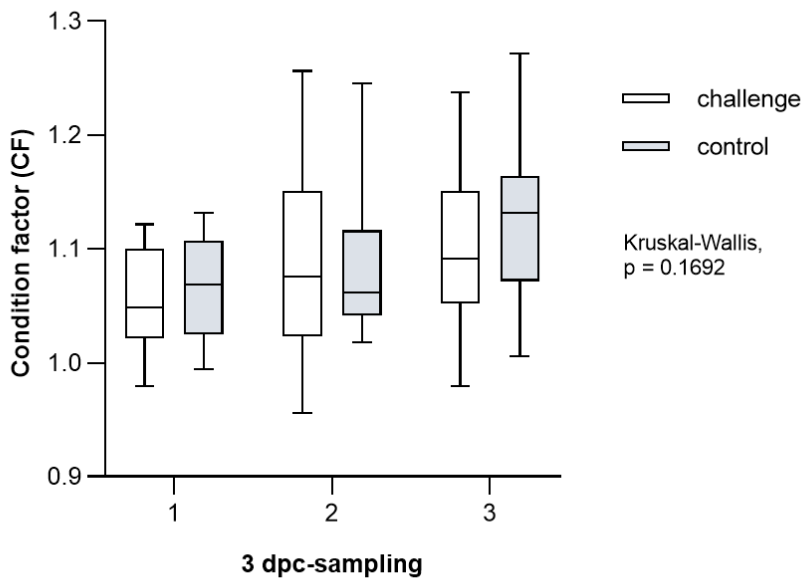
A**B**

Figure 8. Box plot showing mean \pm SD weight (g) and condition factor (CF) of Atlantic salmon smolts sampled 3 days post challenge ($n = 18$ and 12 for challenged and control fish, respectively). The time between sample points was four weeks. **A.** A comparison of weight between each pair was assessed by a two-way ANOVA, showing an increase between time-points ($p < 0.0001$). Different letters indicate significant differences between the groups (Tukey-Kramer posthoc test, $p < 0.05$). **B.** CF, showing no significant differences between time-points (Kruskal-Wallis, $p = 0.1692$).

3.2 Histological analyses

Histological analyses were performed on jaw, ventral, vent, and dorsal 0-samples and 3 dpc-samples (all samples AB-PAS). Analyses include manual and digital measurements of epidermis thickness and number of mucous cells, in addition to observation of morphology and histopathological changes.

3.2.1 Manual measurements of jaw skin-samples

Representative images of jaw epidermis from Area 1 are presented in Figure 9. The jaw epidermis thickness in μm (mean \pm SD) from fish reared in freshwater increased over time, but a different development is observed for fish reared in low strength seawater (Table 3). The development over time (independent of area) is presented in Figure 10 A, showing an increase over time ($p = 0.0012$), but no significant differences regarding water quality ($p = 0.7512$), nor the interaction between them ($p = 0.1078$). There is however a difference in epidermis thickness between areas of the jaw ($p < 0.0001$). Area 1 was thickest followed by Area 2 and Area 3, as presented in Figure 10 B.

Table 3. Epidermis thickness of Atlantic salmon smolts reared in freshwater (F) and low strength seawater (LSS). Table showing the number of jaw samples (n) and the epidermis thickness in μm (mean \pm SD) measured in three different areas of the jaw, Area 1, 2, and 3. The time between sample points was four weeks.

0-sampling		Area 1	Area 2	Area 3
0-sampling 1 n = 6	F	113.3 \pm 42.8	56.7 \pm 19.3	47.9 \pm 21.9
0-sampling 2 n = 12	F	159.7 \pm 48.2	98.7 \pm 38.3	52.4 \pm 11.9
	LSS	183.1 \pm 27.5	137.4 \pm 52.9	73.1 \pm 16.0
0-sampling 3 n = 12	F	212.4 \pm 78.8	145.7 \pm 66.6	80.7 \pm 18.2
	LSS	171.9 \pm 38.1	109.6 \pm 30.5	86.6 \pm 37.7

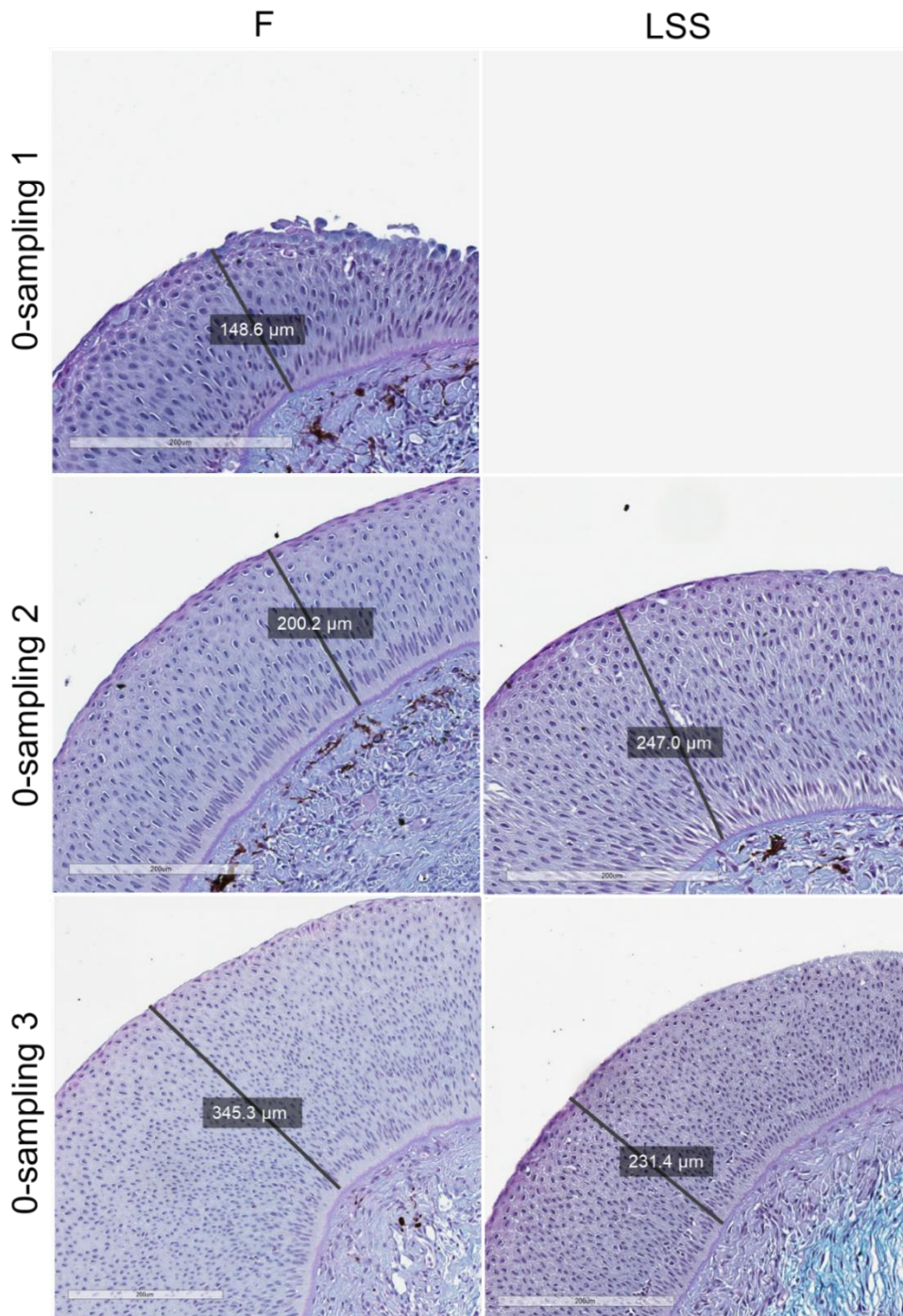
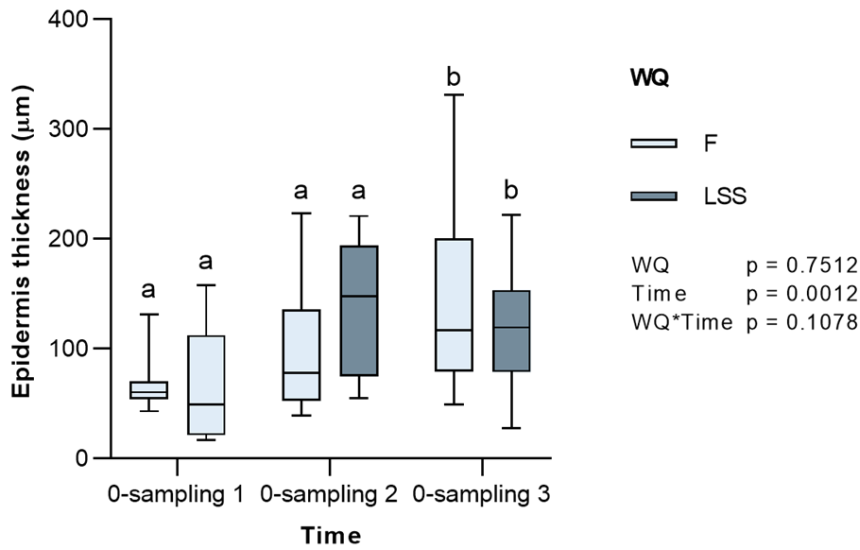


Figure 9. Development of epidermis thickness in Area 1 of the Atlantic salmon jaw, showing 0-samples taken before challenge, from fish reared at two different water qualities, freshwater (F), and low strength seawater (LSS). Samples stained with Alcian blue-Periodic acid-Schiff (AB-PAS). Epidermis layer measured as illustrated by lines. The time between each sampling is four weeks.

A



B

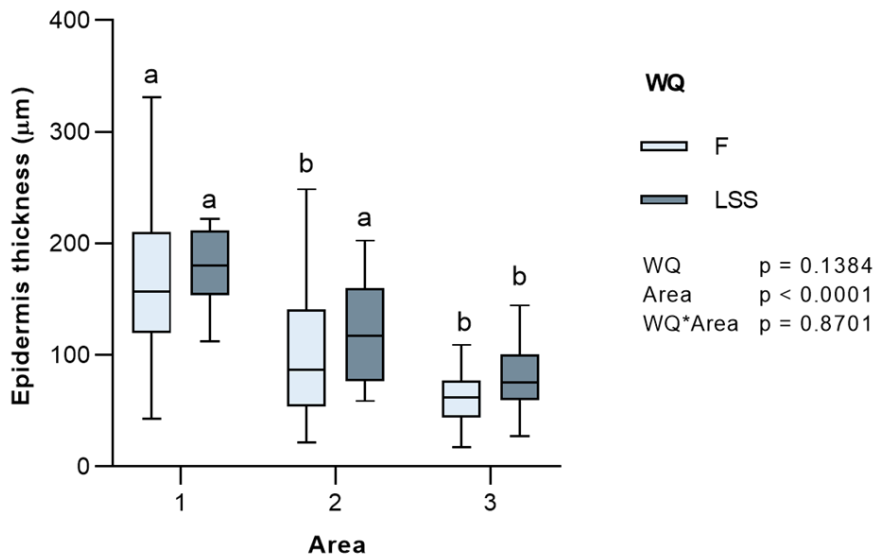


Figure 10. Box plot showing mean \pm SD thickness (μm) of jaw epidermis in Atlantic salmon smolts ($n = 6, 12$ and 12 for 0-sampling 1, 2 and 3, respectively) reared in two different water qualities (WQ), freshwater (F) and low strength seawater (LSS). The time between sample points was four weeks. **A.** Development of jaw epidermis thickness over time, independent of area. **B.** Jaw epidermis thickness per area (Area 1, 2, and 3), independent of time. Area 1 was thickest followed by Area 2 and Area 3. A comparison of mean thickness between each pair was assessed by two-way ANOVA. Different letters indicate significant differences between the groups (Tukey-Kramer posthoc test, $p < 0.05$).

The data for the number of mucous cells in the jaw epidermis was not normally distributed, due to the data varied greatly among individual fish sampled at the same time-point. A Kruskal–Wallis test ($p < 0.0001$) followed by a posthoc Dunn for multiple comparisons was used to show the difference between the three different areas of the jaw, as shown in Figure 11. The percentage of purple and surface mucous cells compared to the total number of mucous cells are summarized in Table 4.

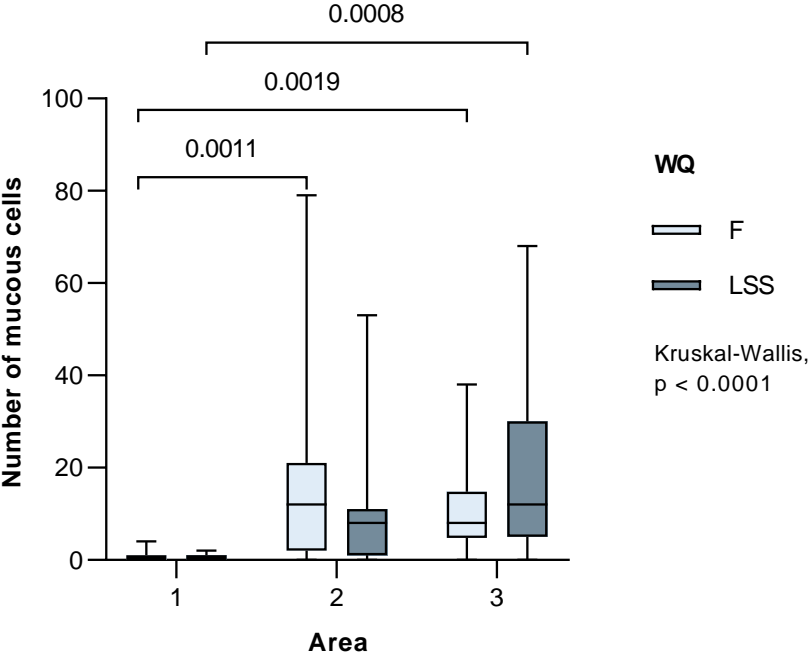


Figure 11. Box plot showing mean \pm SD number of mucous cells in the jaw epidermis per area (Area 1, Area 2 and Area 3) from fish ($n = 30$) reared at to different water qualities (WQ), freshwater (F) and low strength seawater (LSS). A comparison was assessed by the Kruskal-Wallis test ($p < 0.0001$) followed by posthoc test Dunn for multiple comparisons between the groups (brackets with p-value).

Table 4. Measurements of mucous cells in Atlantic salmon smolts reared in freshwater (F) and low strength seawater (LSS). Mean \pm SD number of mucous cells, percentage \pm SD of purple, and surface mucous cells in the jaw epidermis (Area 1, 2, and 3 combined), from 0-sampling 1, 2 and 3. The time between sample points was four weeks.

Sampling	0-sampling 1		0-sampling 2		0-sampling 3	
Water quality	F	F	LSS	F	LSS	
Number of mucous cells	4.75 \pm 4.93	7.87 \pm 7.16	5.06 \pm 8.5	18.22 \pm 22.33	14.78 \pm 19.6	
Percentage of purple mucous cells	3.0 \pm 10.0	1.0 \pm 4.0	1.0 \pm 3.0	1.0 \pm 4.0	0 \pm 0	
Percentage of surface mucous cells	26.32 \pm 36.21	13.56 \pm 18.0	3.70 \pm 8.52	6.10 \pm 7.74	3.01 \pm 3.89	

Correlation between the thickness of the epidermis and the number of mucous cells (both blue and purple) in the jaw epidermis was investigated by Spearman's correlation analysis and the results are presented in Figure 12. A correlation was seen for Area 3 ($r = 0.6075$, $p = 0.0005$), but no correlation was seen for Area 1 ($r = -0.0264$, $p = 0.8983$) or Area 2 ($r = 0.2621$, $p = 0.1778$).

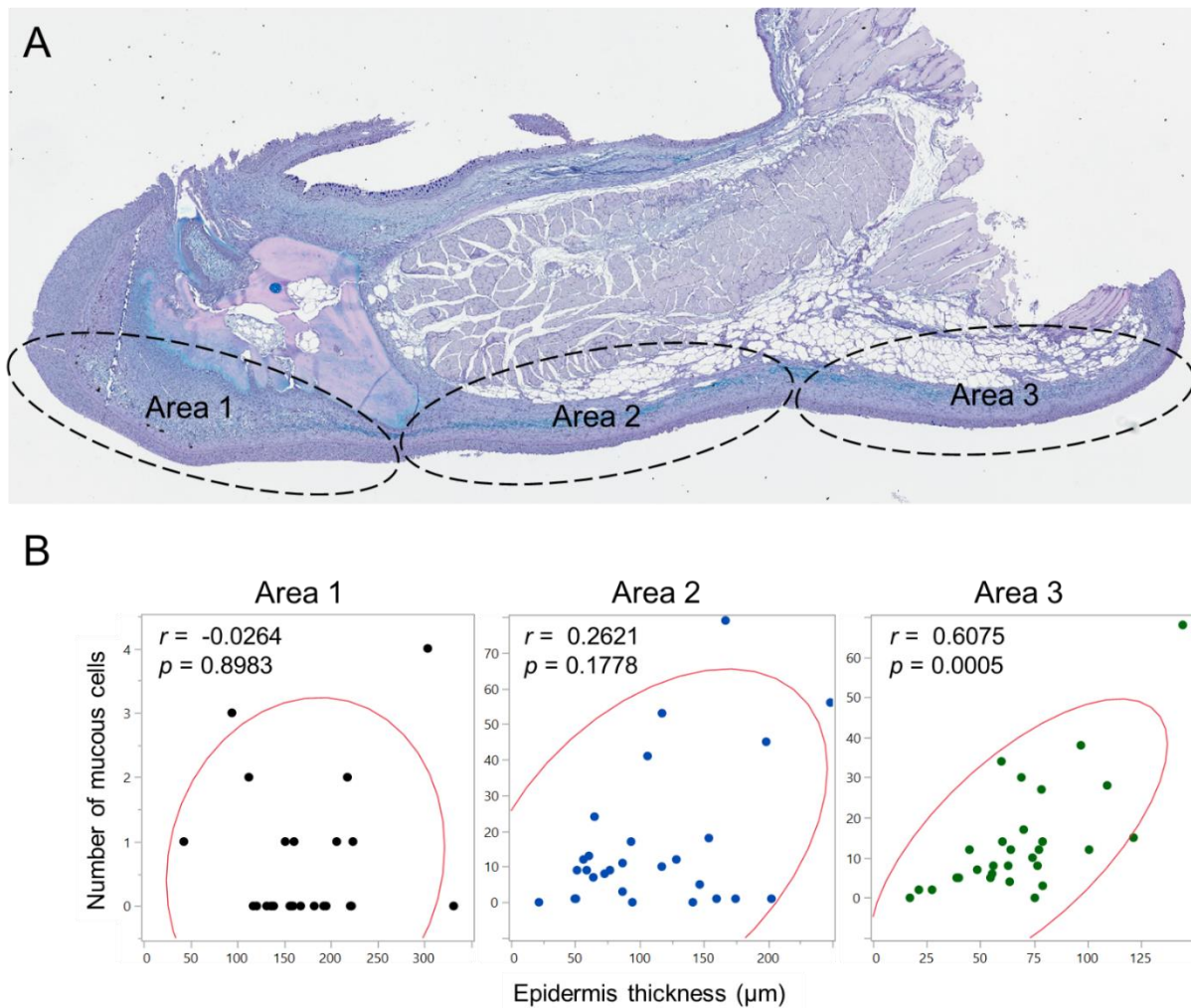


Figure 12. **A.** Overview over Area 1, Area 2, and Area 3 of the jaw. **B.** Correlation between epidermis thickness (μm) and the number of mucous cells in the jaw epidermis (0-sampling 1, 2, and 3 combined). Spearman rank correlation coefficients (r) and p -values between the mucous cell numbers and epidermis thickness in three different areas of the jaw, Area 1 ($r = 0.0264$, $p = 0.8983$), 2 ($r = 0.2621$, $p = 0.1778$) and 3 ($r = 0.6075$, $p = 0.0005$). Statistical analysis and presentation of data by Nofima researcher. Graphs are slightly modified.

3.2.2 Digital measurements of ventral and vent skin-samples (Aiforia®)

A selection of results from the digital measurements of ventral and vent skin-samples (AB-PAS) are summarized in Figure 13, showing the development of measured variables epidermis area (μm^2) and mucous cells per mm of skin-sample from fish reared at two different water qualities, F and LSS. The results suggest a similar development for the epidermis and mucous cells in both tissues. Ventral epidermis thickness was significantly different regarding time ($p = 0.011$) but not water quality ($p = 0.556$). Similarly, vent epidermis thickness was significantly different regarding time ($p = 0.0001$), not water quality ($p = 0.556$). Few effects were observed for dorsal samples regarding water quality nor time, and therefore the data is not included in the results.

The same development is seen for the number of mucous cells per mm skin-sample. Mucous cells in ventral samples were significantly different regarding time ($p = 0.049$) but not water quality ($p = 0.408$). Also, mucous cells in vent samples were significantly different regarding time ($p = 0.007$), not water quality ($p = 0.363$). The percentage of purple ventral mucous cells was significantly different regarding water quality ($p = 0.041$), but not time ($p = 0.373$). However, the percentage of purple vent mucous cells were not significantly different regarding water quality ($p = 0.083$) nor time ($p = 0.604$). Placement of the ventral mucous cells (closest distance to epidermis outer border) was significantly different regarding time ($p = 0.026$) but not water quality ($p = 0.706$). Likewise, the placement of vent mucous cells was significantly different regarding time ($p < 0.001$) not water quality ($p = 0.963$). In ventral skin-samples, the epidermis thickness strongly correlates to the number of mucous cells per mm skin-sample ($r = 0.95$, $p < 0.001$). In the vent skin-samples the correlation is almost as strong ($r = 0.84$, $p < 0.001$).

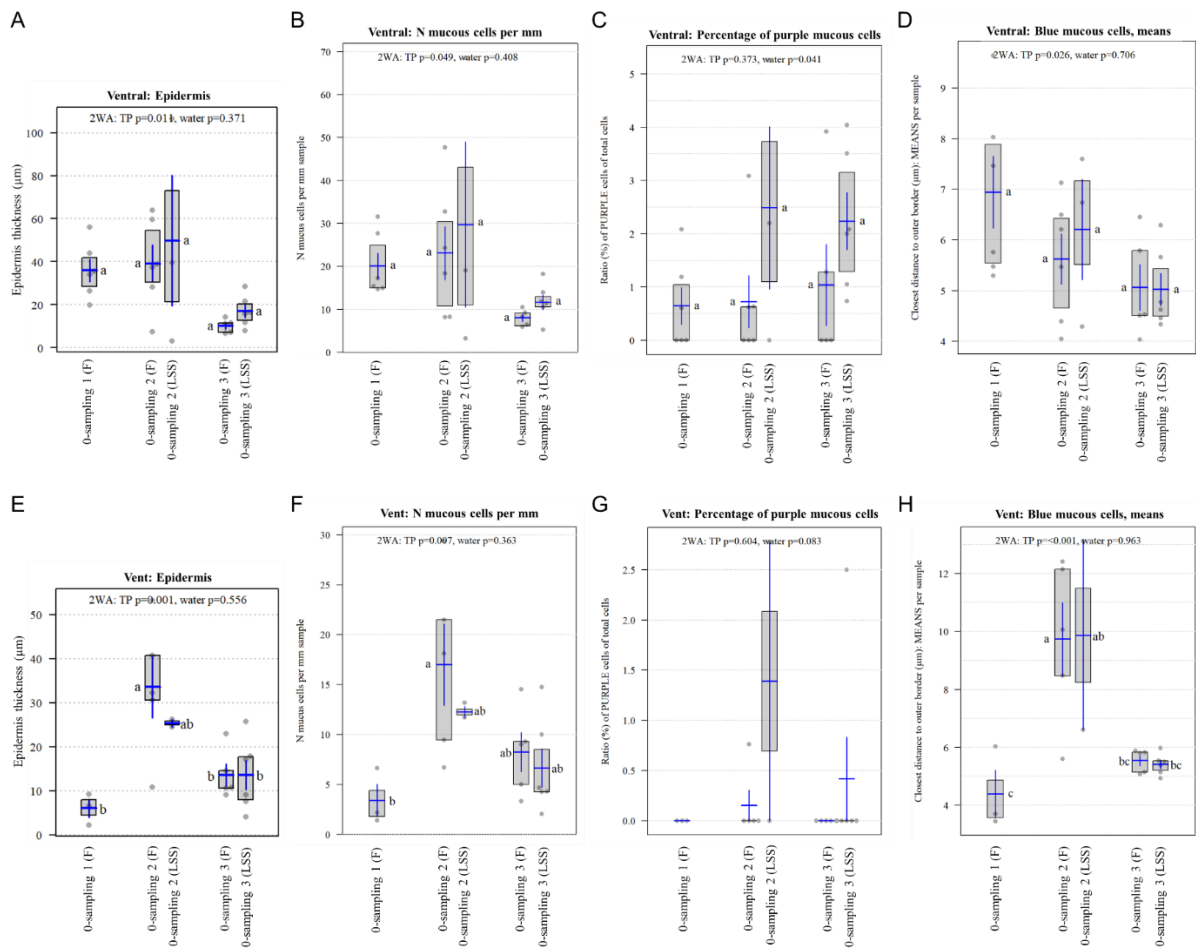


Figure 13. Aiforia® analysis data from ventral (n = 48) and vent (n = 42) skin 0-samples. Box plots showing the development of measured variables epidermis thickness (µm) and mucous cells from fish reared at two different water qualities, freshwater (F) and low strength seawater (LSS) from three different time-points (TP). The time between 0-sampling 1, 2, and 3 is four weeks. **A and E.** Epidermis thickness. **B and F.** Number of mucous cells per mm. **C and G.** Ratio of purple mucous cells of total mucous cells. **D and H.** Distance to epidermis border of blue mucous cells. Aiforia® analysis, statistical analysis, and presentation of data by researchers at Nofima, Ås. Graphs are slightly modified.

3.2.3 Description of histopathological changes

Jaw and ventral 3 dpc-samples (AB-PAS) from challenge 2F & 2LSS and 3F & 3LSS were investigated for overall morphology and histopathological changes. Samples from 1F are not included due to the low development of clinical disease signs and low mortality after challenge. Challenged fish were compared to control fish. Also, differences between fish reared in freshwater and fish reared in low strength seawater was investigated. One feature common for all groups (both jaw and ventral) is the large variation within groups in terms of tissue damage and inflammatory response, ranging from little to widespread damage and infection with *T. finnmarkense*. Tissue damage includes rupture of surface epithelium, degradation, vacuolization, and necrosis. In a few cases, tissue damage was observed in all layers of the skin, including the hypodermis and muscle tissue. Despite the large variation within challenge groups, two groups stood out regarding histopathological changes. In group 2F and 3F, severe tissue damage in the epidermis, as well as the dermis and hypodermis, were observed in association with large numbers of bacteria resembling *Tenacibaculum* spp., in addition to infiltration of inflammatory cells.

Jaw samples

Histopathological changes observed in the jaw samples are presented in Figure 14. A frequent observation among jaw samples was a complete loss of epidermis at the tip of the jaw (Area 1), with infiltration of immune cells in the dermis layer underneath. In some cases, an abrupt change from complete loss of epidermis to intact epidermis was observed (Figure 14 A). In other samples, the epidermis was intact, but suffered from tissue damage, including rupture of surface epithelium, vacuolization, and degeneration (Figure 14 B). A varying degree of pseudopodium-structures (arm-like projections from the cell) was observed in both challenge and control samples with different degrees of tissue damage (Figure 14 C). Vacuolization of the basal epithelium (Figure 14 D) was observed more frequently in fish reared in F than in LSS (Appendix 4). In general, fish reared in F had poorer skin surface compared to LSS (Appendix 4). In more affected samples, histopathological changes were observed in all layers of skin, including dermis and hypodermis. In such samples, the epidermis layer was completely or partly lost (Figure 14 E), with vacuolization and degeneration, and infiltration of inflammatory cells in the dermis and hypodermis layer (Figure 14 F - G). Inflammation was observed in close proximity to tissue damage of the epidermis as well as the dermis. Some of the samples also had bacteria in the dermis layer (Figure 14 G - H). Limited changes were observed in most control samples (Figure 14 I), however, a few control samples from all groups showed tissue

damage and/or complete loss of epidermis, in addition to infiltration of inflammatory cells (Figure 14 J).

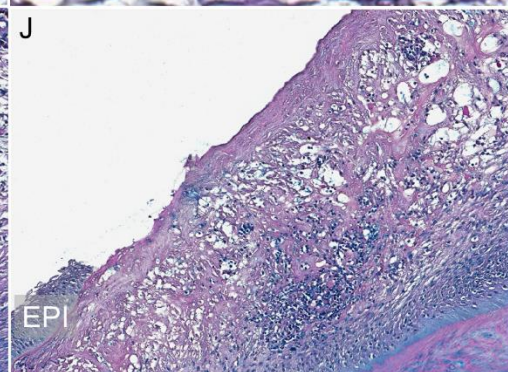
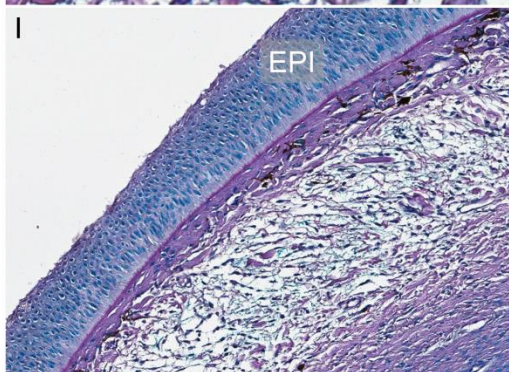
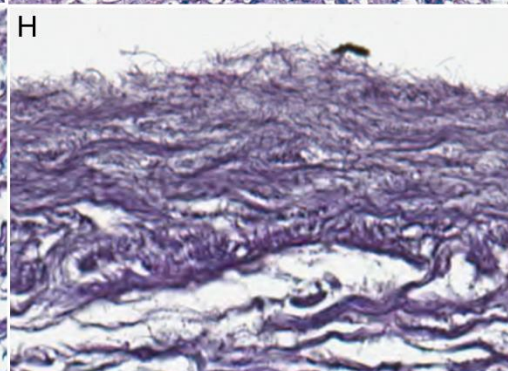
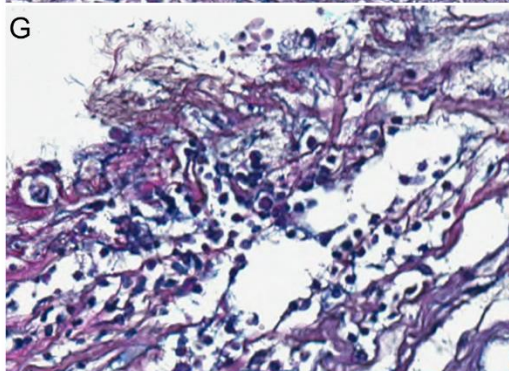
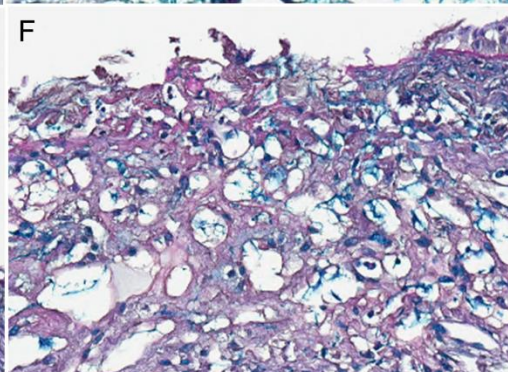
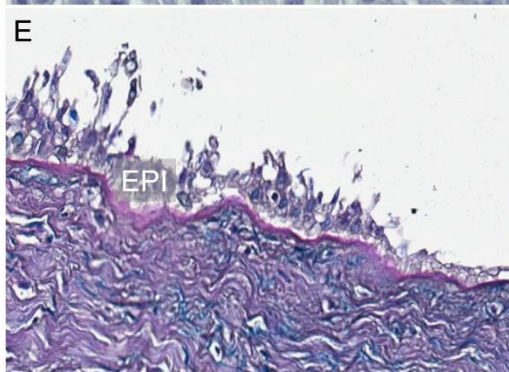
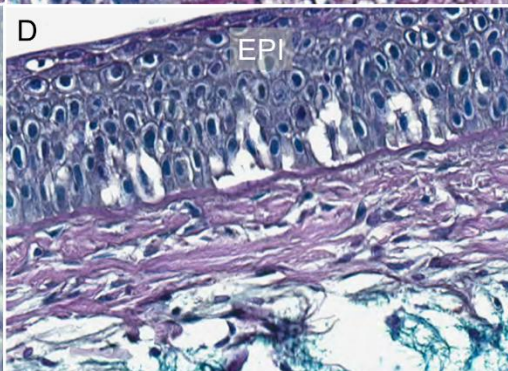
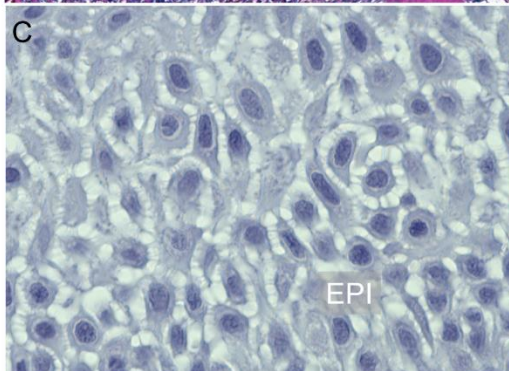
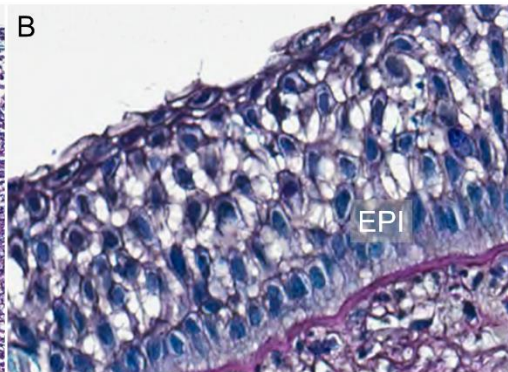
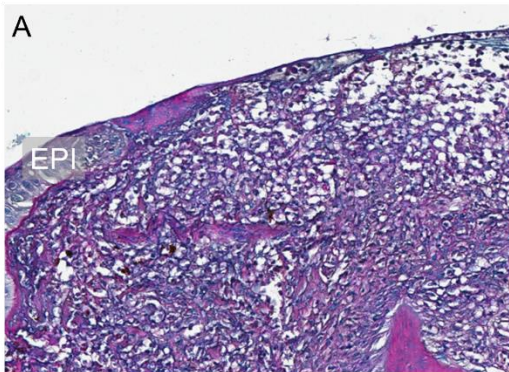


Figure 14. Representative images showing typical histopathology in jaw skin-samples from Atlantic salmon smolts 3 days post challenge. **A.** Complete loss of epidermis at the tip of the jaw (Area 1), and infiltration with immune cells in the dermis layer. **B - C.** Rupture of surface epithelium and loss of tissue structure, with arm-like projections between cells in the epidermis. **D.** Vacuolization of the epidermis. **E.** Severe loss of tissue structure in the epidermis. **F - G.** Loss of tissue structure and infiltration of inflammatory cells in the dermis layer **H.** Thick layer of tread-like bacteria replacing the epidermis. **I.** Control sample, showing intact epidermis and dermis. **J.** Control sample, showing rupture of the epidermis and infiltration of inflammatory cells. Epidermis (EPI).

Ventral and vent skin-samples

Moderate to severe tissue damage was observed in ventral and vent skin-samples. Tissue damage included loss of scales, vacuolization, and loss of structure in the epidermis, and infiltration of polymorphonucleated inflammatory cells in the loose connective tissue (Figure 15 A - C). Also, a frequent finding was dilated blood vessels in the dermis of challenged samples (Figure 15 D), but not in controls. This was present in samples with both moderate and more severe tissue damage. In samples with severe tissue damage, changes were observed in all layers of the skin and the subcutaneous layers. Samples with widespread infection showed similar histopathological changes, including complete loss of the epidermis and scales, partial loss of tissue structure in the loose connective tissue in the dermis, and melanophore and adipose tissue in the hypodermis as well as degeneration and necrosis of muscle fibers (Figure 15 D). Infiltration of immune cells in connective tissue (Figure 15 E) and a thick layer of bacteria-like structures was also observed (Figure 15 F). Most control samples were unaffected (Figure 15 G), however, some control samples displayed a thinner, sometimes ruptured epidermis (Figure 15 H).

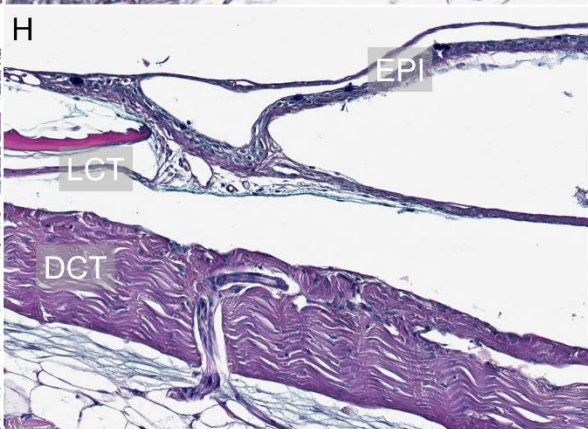
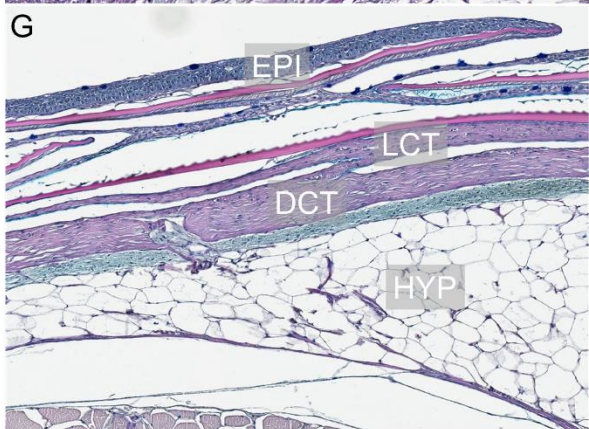
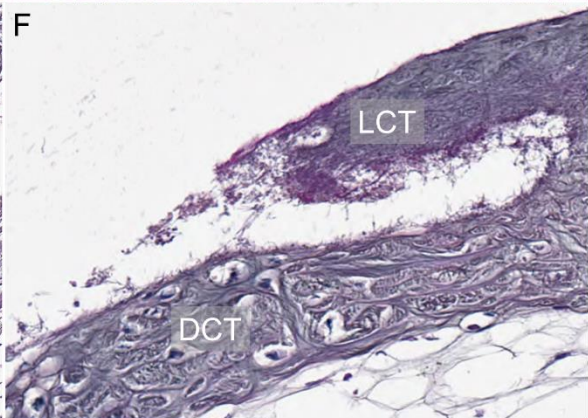
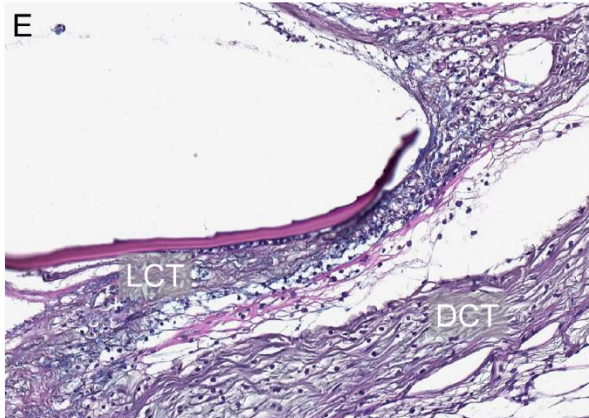
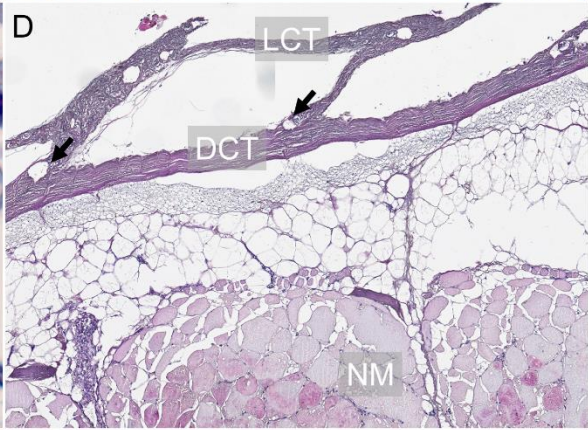
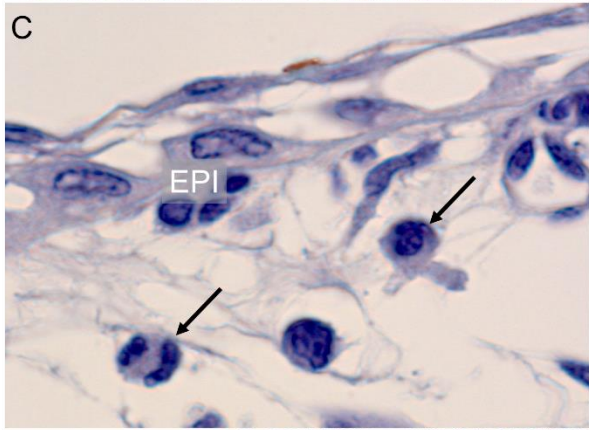
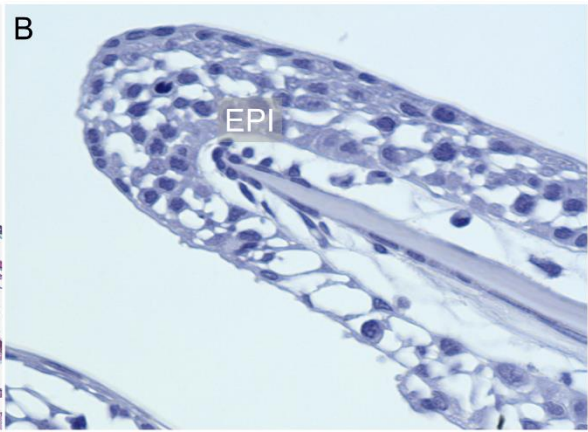
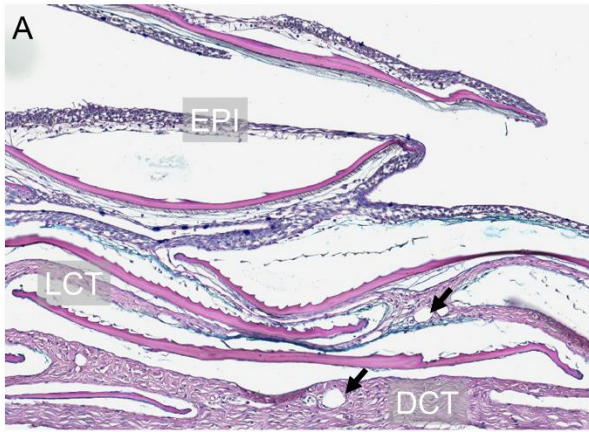


Figure 15. Representative images showing typical histopathology in ventral skin-samples from Atlantic salmon smolts 3 days post challenge. **A.** Vacuolization and loss of tissue structure in the epidermis with dilated blood vessels in the dermis layer. **B - C.** Loss of tissue structure and infiltration of polymorphonucleated inflammatory cells (thin arrows) in the epidermis. **D.** Complete loss of epidermis and scales dilated blood vessels in loose connective tissue (bold arrows), and necrosis of muscle fibers. **E.** Infiltration of immune cells in loose and dense connective tissue. **F.** Loss of tissue structure in loose connective tissue infiltrated with thread-like structures. **G.** Control sample showing intact epidermis, dermis, and hypodermis. **H.** Control sample, with a thinner and ruptured epidermis. Epidermis (EPI), loose connective tissue (LCT), dense connective tissue (DCT), necrotic muscle (NM), hypodermis (HYP).

3.2.4 Immunohistochemistry

Selected samples for immunohistochemistry were examined microscopically. Positive sections were stained bright red, revealing long rod-shaped bacteria, confirming the presence of *T. finnmarkense*. The bacterium was observed in all layers of the skin, including the epidermis, dermis, and the hypodermis layer, however, most frequently observed in the dermis, with the highest abundance closest to the outer dermis. Individual bacteria were observed deeper in the lesion, and rarely in the epidermis. The presence of the bacterium was often accompanied by an immune response. However, inflammation was also observed in some samples with no or very little positive staining for bacteria.

Jaw skin-samples

Typical findings in positive samples were *T. finnmarkense* in close proximity to the affected epidermis (Figure 16 A – C, Figure 17 A – C). In most cases, the bacterium was observed at the tip of the jaw (Area 1). In a few cases, the epidermis was completely lost and replaced by a thick layer of bacteria (Figure 16 A – B). *T. finnmarkense* was rarely observed within the epidermis. The bacteria were observed abundantly in the dermis layer right under the epidermis, randomly organized in dense and loose connective tissue.

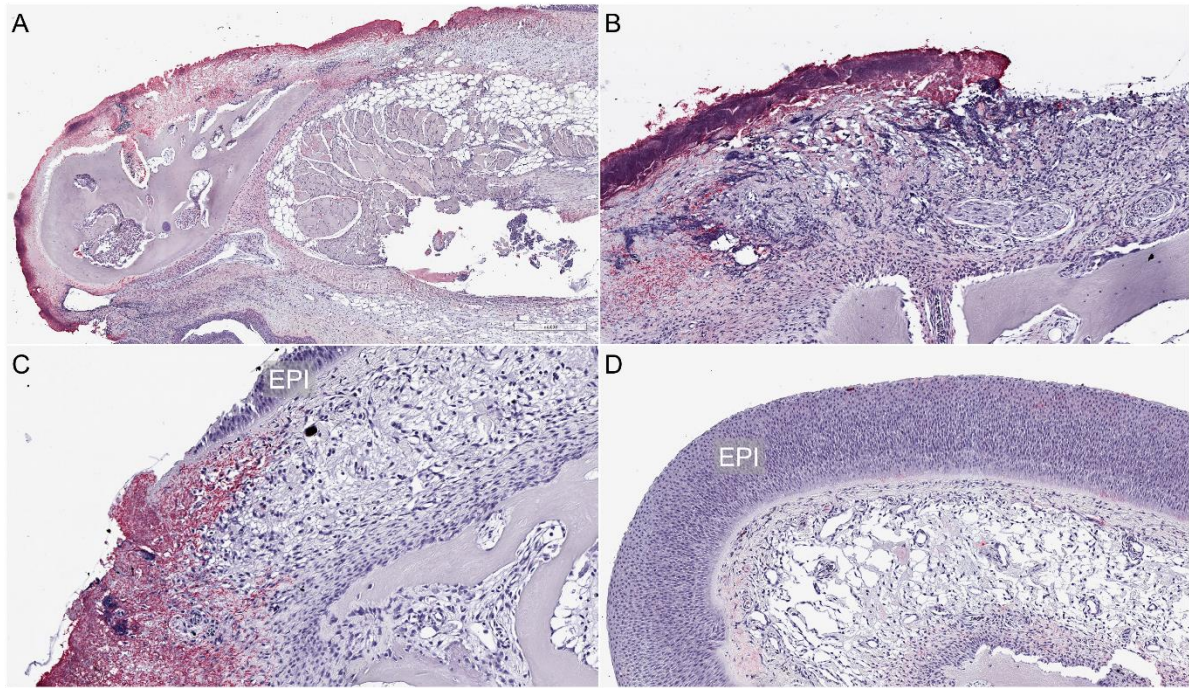


Figure 16. Jaw samples stained using immunohistochemistry, showing an overview of samples with widespread infiltration with *T. finnmarkense* (positive samples stained bright red) from Atlantic salmon smolts 3 days post challenge. **A - C.** Challenged, showing partial or complete loss of epidermis, and massive infiltration of bacteria. **D.** Control samples with intact epidermis and negative for *T. finnmarkense*. Epidermis (EPI).

Investigating the sections at higher magnification revealed bacteria in close proximity to the affected epidermis (Figure 17 A - C). *T. finnmarkense* was typically observed in the top layer of the dermis (Figure 17 D). Also, the bacteria were observed transitioning between layers of the skin through anchoring points of connective tissue (Figure 17 E). In the hypodermis, the bacteria were randomly organized, but observed in close proximity to blood vessels (Figure 17 F).

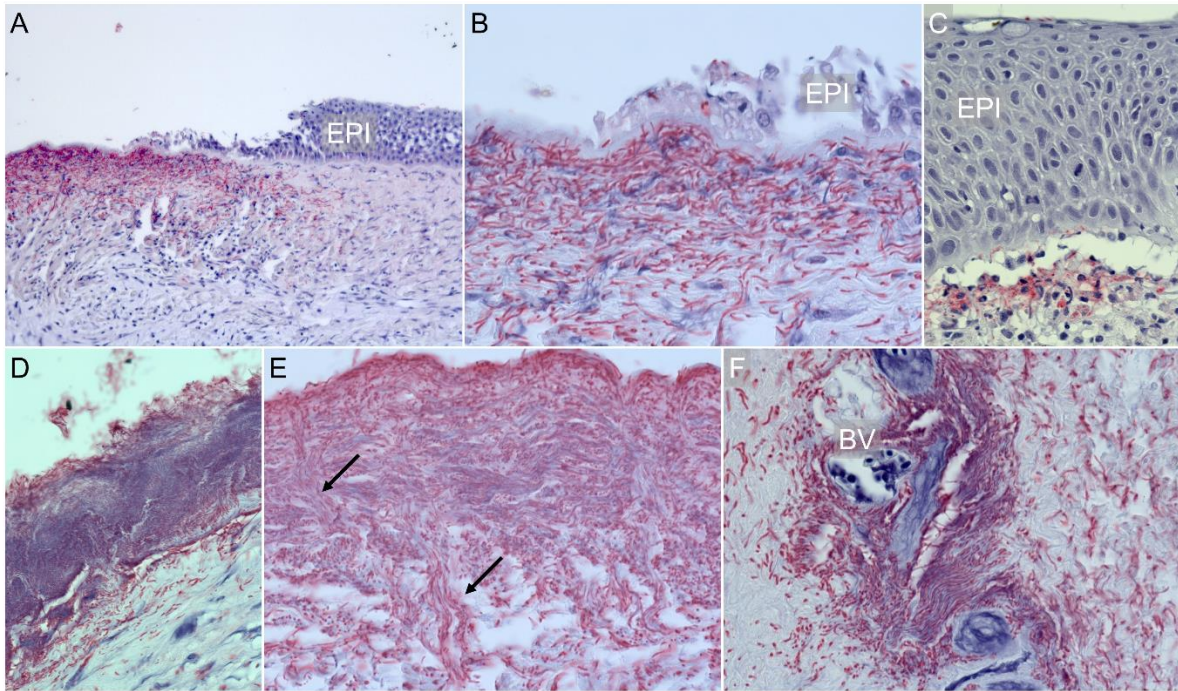


Figure 17. Jaw samples stained using immunohistochemistry, showing infiltration with *T. finnmarkense* (positive samples stained bright red) from Atlantic salmon smolts 3 days post challenge. **A - C.** Rupture and loss of tissue structure in the epidermis. **D.** A thick layer of bacteria in the dermis layer underneath the epidermis. **E.** *T. finnmarkense* transitioning between layers of skin in the dermis layer through connective tissue (arrows). **F.** The bacterium in the hypodermis layer surrounding blood vessels. Epidermis (EPI), blood vessel (BV).

Ventral skin-samples

T. finnmarkense was typically observed in loose and dense connective tissue and inside scale pockets in association with inflammatory cells (Figure 18 A and C - D). When present in the epidermis, the bacterium was associated with loss of tissue structure and parts of the epithelium “peeled” off (Figure 18 A). Inflammation was observed also without the presence of bacteria (Figure 18 B). In samples heavily infected, the *T. finnmarkense* was observed also in the subcutaneous layers of the skin, associated with the myocommata close to the vent (Figure 18 D - E). None of the control samples stained positive for *T. finnmarkense* (Figure 18 F).

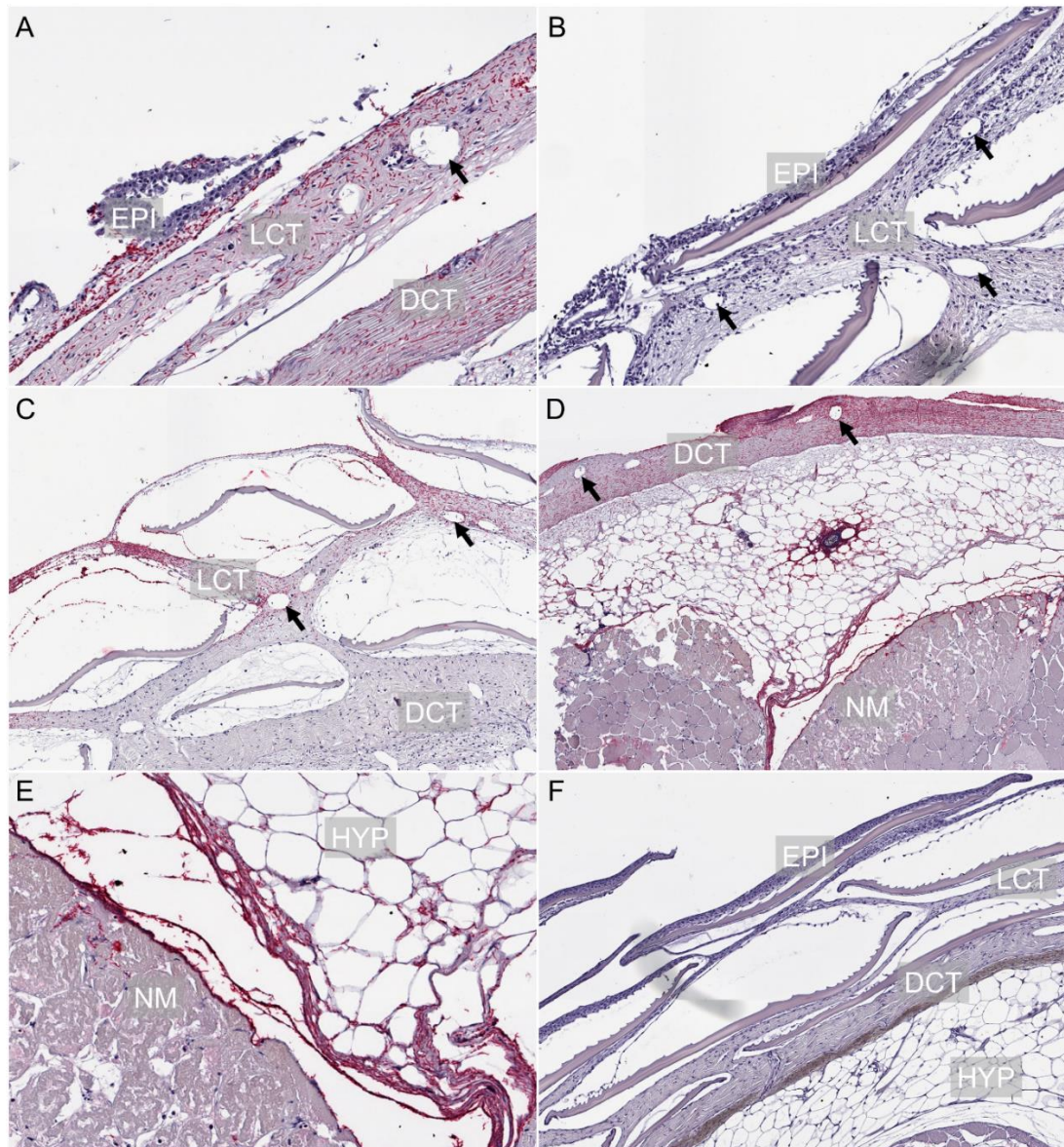


Figure 18. Ventral skin-samples stained using immunohistochemistry, showing an overview of samples with widespread infiltration with *T. finnmarkense* (positive samples stained bright red) from Atlantic salmon smolts 3 days post challenge. **A.** Epidermis «peeling» off. **B.** Loss of tissue structure and infiltration of immune cells in the epidermis and loose connective tissue. Dilated blood vessels (arrows) without the presence of bacteria. **C.** Infiltration of bacteria in loose connective tissue and inside scale pockets. Dilated blood vessels (arrows). **D.** Loss of epidermis and scales dilated blood vessels (arrows). Bacteria is observed in dense connective tissue as well as in the subcutaneous layers of skin, down to the muscle. **E.** Bacteria in the hypodermis layer, in myocommata, in close proximity to necrotic muscle. **F.** Control sample with intact epidermis, scales, connective tissue, and hypodermis. Epidermis (EPI), loose connective tissue (LCT), dense connective tissue (DCT), hypodermis (HYP), necrotic muscle (NM).

Investigating sections on higher magnification revealed *T. finnmarkense* loosely organized in loose connective tissue (Figure 19 A), while in dense connective tissue the bacterium was observed oriented between alternating collagen fibers (Figure 19 B - C). Interestingly, the bacteria were observed transitioning from loose connective tissue to dense connective tissue (Figure 19 D - E) and from dense connective tissue to hypodermis (Figure 19 F) through anchoring points. Bacteria were observed surrounding scales (Figure 19 G) and blood vessels (Figure 19 H - I).

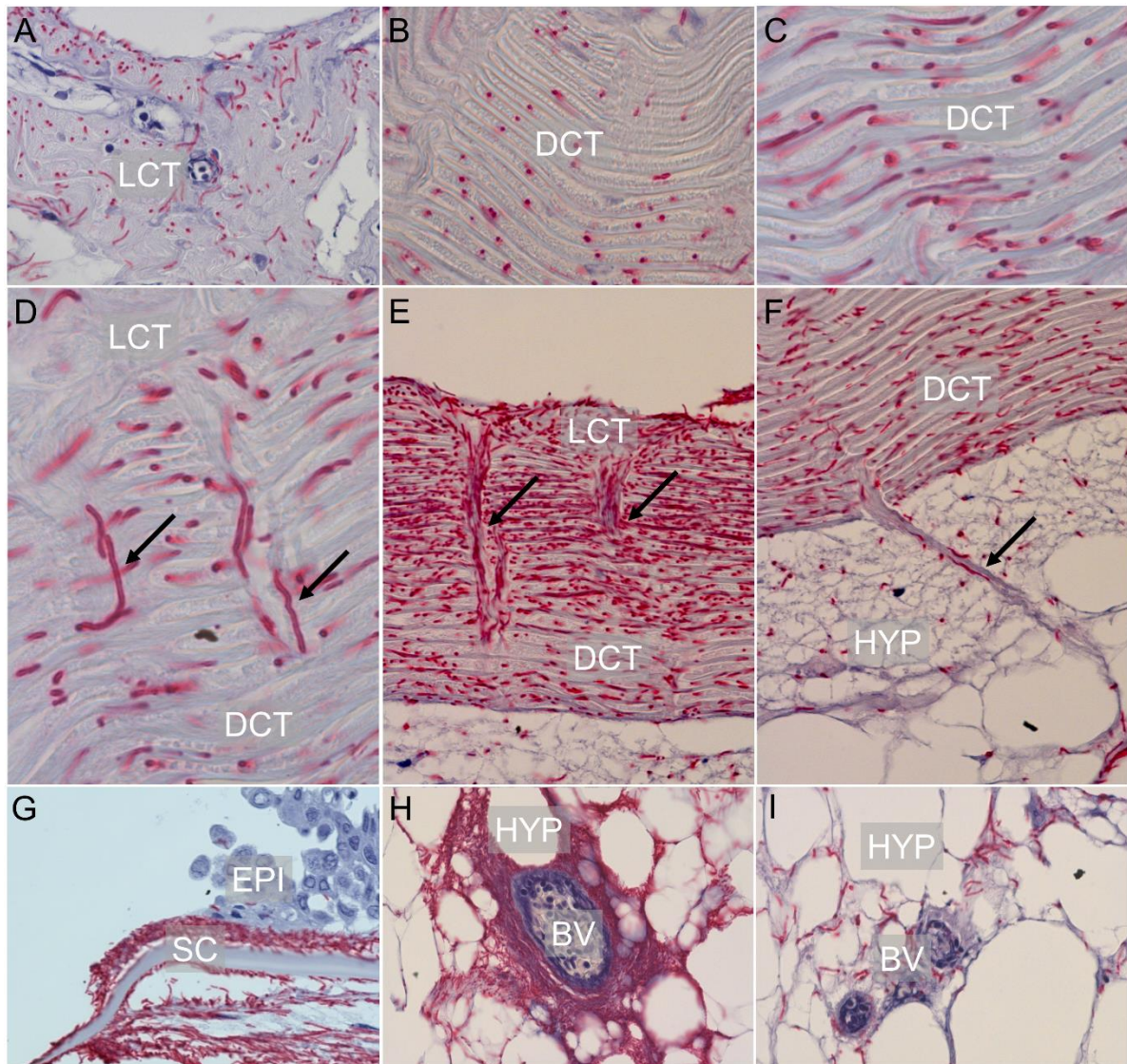


Figure 19. Ventral samples stained using immunohistochemistry, showing infiltration of *T. finnmarkense* (positive samples stained bright red) from Atlantic salmon smolts 3 days post challenge. **A.** Bacteria randomly organized in loose connective tissue. **B - C.** Bacteria in dense connective tissue, following the alternating orientation of the collagen fibers. **D - E.** Bacteria transitioning from loose connective tissue to dense connective tissue through connective tissue (arrows). **F.** Bacteria in anchoring points (arrows) between dense connective tissue and hypodermis. **G.** Bacteria surrounding scales in close proximity to the ruptured epidermis. A few bacterial cells can be seen in the epidermis. **H - I.** Bacteria in the hypodermis, surrounding blood vessels filled with blood cells. Loose connective tissue (LCT), dense connective tissue (DCT), scales (SC), hypodermis (HYP), blood vessel (BV).

3.3 Gene expression

The microarray results presented in this thesis are meant to give an overview of the overall effect of *T. finnmarkense* infection on gene transcription patterns in the epidermis and dermis. A selection of results from the microarray analysis of the epidermis and dermis from ventral skin-samples from 3 dpc-sampling 1F and 2F & 2LSS are presented in Appendix 6. The transcription profile includes patterns of selected immune, cell, and tissue gene categories in the epidermis and dermis between the experimental groups. Differentially expressed genes (DEG) are organized in gene groups, which are either increased or decreased in expression.

The results indicate high similarity in gene transcription profiles between the epidermis and the dermis layer. Within the tissue layers, a pattern indicating the up-regulation of immune genes, down-regulation of cell renewal genes, and up-regulation of cell stress/apoptosis genes was observed. For the immune genes, infection with *T. finnmarkense* stimulates a range of protective immune responses in the skin triggered by host immune regulators including chemokines, cytokines, and eicosanoids. Other immune genes coding for lymphocytes, B-cells, and antigen-presentation are also up-regulated in both tissues. The up-regulation of cell stress and apoptosis genes suggest that the tissue was suffering from damage. Erythrocyte and plasma genes are up-regulated, indicating increased blood flow to both tissues. Also, the group of iron heme is upregulated in dermis indicating iron to be of relevance in infected tissue. In parallel to the up-regulation of immune genes, a down-regulation of different factors involved in tissue and cellular development was observed, including DNA replication, tissue differentiation and cytoskeleton keratin.

4 Discussion

A newly emerging disease, tenacibaculosis, has inflicted a substantial load on the Norwegian salmon farming industry the last years, leading to increased mortalities, reduced fish welfare, and higher use of antibacterial drugs. Little is known about factors that trigger disease, or which are involved in the pathogenicity of the causative agent, *T. finnmarkense*. New development in smolt production strategies allows a different approach to today's production strategies, where the fish are transferred to seawater net-pens directly from freshwater when smoltified. Increased production of post-smolt on land is a strategic focus to reduce mortality in the period after sea transfer (Sommerset et al., 2020). This thesis investigates the effect of environmental conditions and smolt size on the susceptibility for infection with *T. finnmarkense*. The different rearing conditions, freshwater, and low strength seawater, and the time before transmission to seawater and exposure to the bacterium, represents different sea transfer strategies in Atlantic salmon farming.

4.1 Salmon smolts stocked at higher salinity have lower mortality when challenged with *T. finnmarkense*

Results of Solheim (2020) indicate an effect of both water quality and smolt size on mortality, and susceptibility of infection with *T. finnmarkense*. In Trial 2, the accumulated mortality was higher in challenge 2F (48 %) compared to 2LSS (20 %). Likewise, in Trial 3 the accumulated mortality was higher in challenge 3F (25 %) than in 3LSS (12 %). The effect of water quality is also reflected in the welfare scoring conducted at the samplings, with most ulcers observed in fish reared in F (Appendix 2). However, the F fish had better growth (Figure 7, Figure 8) and had fewer cases of production disorders (Appendix 2). The same trends as for mortality rates were observed in the rt qPCR results (Solheim, 2020) with higher a prevalence of *T. finnmarkense* in F fish than in LSS fish, for Trial 2 and 3. The rapid development in mortality at the beginning of the trials, suggests an acute disease progression, similar to what has been described in other challenge experiments (Småge et al., 2018) and field outbreaks (Småge et al., 2017). Comparing Trial 2 and 3 shows a higher mortality rate and higher prevalence of *T. finnmarkense* in challenge 2F compared to 3F. Although the positive effect of a larger smolt size is indicated, Trial 2 and 3 cannot be compared directly because firstly, they are two independent trials in time, and secondly, they used two different bacterial batches where the infection dose used in challenge 3F was (slightly) higher compared to 2F.

Several factors are known to affect growth and pathogenicity of fish skin pathogens, including salinity (Tunsjø et al., 2007). The effect of salinity on growth and pathogenicity of *T. finnmarkense* is not well-studied. It is, however, described in other members within this taxon, including *T. maritimum* (former *Flexibacter maritimus*). It has been shown that the salinity below 15 ppt can reduce the growth rate of this bacterium, and therefore fish mortalities in salmonid fish (Soltani & Burke, 1995). This was supported by Soltani, Munday, and Burke (1996), showing reduced salinity below 15 ppt alters the development of skin erosion disease caused by *T. maritimum*.

Salinity is also shown to affect the performance and welfare of fish. A recent study showed that recirculated brackish water (12 ppt) had positive effects on Atlantic salmon smolt growth and survival compared to full-strength seawater (Ytrestøyl et al., 2020). The positive effect of rearing smolt at 12 ppt was demonstrated on survival post sea transfer (Calabrese, 2017; Ytrestøyl et al., 2015). Thus, adapting the smolt to full-strength seawater and allowing bigger smolt before sea transfer could influence susceptibility to tenacibaculosis. The use of RAS for smolt production would allow better control of the environmental conditions and likely protection against some infectious diseases, although successful production in RAS would require good biosecurity and control over the water quality parameters (Sommerset et al., 2020). By producing a bigger post-smolt in land based brackish water RAS before sea transfer could make the fish more robust and be less susceptible to infection (Ytrestøyl et al., 2020), however, more research on this field is required.

Further, using strategies that will reduce fish interaction with infectious agents the first period after sea transfer (i.e. closed or semi-closed systems) is suggested as an important factor when reducing mortality and increasing fish welfare, as the fish in this period shows signs of temporary immune suppression (Johansson, Timmerhaus, Afanasyev, Jørgensen, & Krasnov, 2016; Karlsen et al., 2018). The drop in immune function could lead to increased susceptibility to pathogens and the risk of developing disease like tenacibaculosis. The majority of salmonids dying in Norwegian aquaculture die within 0-3 months post sea transfer (Bleie & Skrudland, 2014; Sommerset et al., 2020). The use of land-based facilities for the production of larger post-smolts and production in closed or semi-closed systems in the sea are increasing in Norway (Sommerset et al., 2020), reflecting the need for new production strategies to lower mortality and increase fish welfare in the industry. Results from this current study could be of importance regarding the design of future smolt facilities in terms of temperature and salinity.

4.2 Weight and condition factor

The fish were sampled at the beginning of the experiment (i.e. 0-sampling 1), right after smoltification, and before the fish were divided into F and LSS (Figure 3). This fish represents the starting point for the fish in Trial 1, 2, and 3. The weight of fish sampled before challenge (from the production facility) increased between all time-points in both water qualities. However, differences in growth development between water qualities were observed. The weight of F fish was higher than of LSS fish for all time-points. The recent study of Ytrestøyl et al. (2020) showed that the growth rate of Atlantic salmon smolts was positively affected by lower salinity and higher water velocity, but that this also was influenced by fish size. Previous studies have demonstrated that growth of Atlantic salmon smolts was temporarily inhibited by increased salinity to 20 and 34 ppt compared to 0 and 10 ppt (Duston, 1994) and similar results have been reported from Rainbow trout and Chinook salmon (*Oncorhynchus tshawytscha*) (Morgan & Iwama, 1991), and turbot (*Psetta maxima*) (Dietz, Stiller, Griese, Schulz, & Susenbeth, 2013). Teleost fish have in general, higher growth in brackish water compared to seawater (Boeuf & Payan, 2001). However, growth is also highly dependent on temperature, and growth is likely effected by both parameters (Handeland, Berge, Björnsson, & Stefansson, 1998; Imsland et al., 2001).

Also, the weight of challenged fish increased over time, and no differences were observed between challenged and control fish within challenge groups. The condition factor (CF) dropped significantly after the first sampling, i.e. 0-sampling 1. For the remaining samplings, the CF was at a lower but consistent level. A strong positive correlation between total lipid content and CF has previously been reported from Atlantic salmon parr (Herbinger & Friars, 1991). The drop in CF from this study could thereby be explained by natural changes in fat and protein deposition during the post-smolt period.

4.3 Salinity and growth effects on skin morphology

For fish sampled before challenge, morphological variables, epidermis thickness, and mucous cell number and characteristics were measured histologically. The thickness of the jaw epidermis increased over time for fish reared in F. However, in LSS fish, the jaw epidermis developed differently. Here, the thickness of the epidermis decreased over time. No effects were observed in the number of mucous cells. One challenge with the mucous cell data is that the number of mucous cells varied greatly between individuals within sample groups. This is

affecting the accuracy of predictions, which could have been strengthened by increasing the number of samples used. Ventral and vent epidermis thickness developed over time but was not affected by water quality. Again, the low number of samples with high individual differences produce few significant results. However, the correlation between epidermis thickness and the number of mucous cells in ventral and vent-skin samples is strong, as previously described by Karlsen et al. (2018). In contrast, the jaw samples epidermis and the number of mucous cells is only sparsely correlated in Area 3 of the jaw. In Area 1 and Area 2 of the jaw, no correlation was observed. However, Area 1 has the thickest epidermis, but the least number of mucous cells. This suggests differences in the composition of the skin in the head region. A difference between the dorsal and ventral side of the fish is previously reported by Pittman et al. (2013). The recent study by Ytrestøyl et al. (2020) found increased salinity affecting the skin surface morphology negatively, which was also mirrored by up-regulation of stress markers while downregulated expression of mucus markers and the number of mucous cells (Ytrestøyl et al. 2020). In general, salinity as an environmental factor has a major influence on skin morphology.

4.4 Pathological findings

The main pathological findings in the challenge trials were scale loss, ulcers of various degree, and yellow-pigmented skin. Ulcers typically developed on the jaw, ventral skin, and fins. However, most were located on the jaw and ventral part of the fish (Appendix 2). These are areas where abrasions can easily occur in both field and experiments, for example when fish are in contact with the bottom of tanks or tank walls or exhibit aggressive behavior like biting of fins (Noble et al., 2018). Skin abrasion could allow the bacteria to establish an infection (Bornø et al., 2011; van Gelderen, Carson, & Nowak, 2011). However, the same strain used in this challenge experiment have previously induced tenacibaculosis in another challenge experiment resulting in skin lesions, mouth erosions and frayed fins without manually induces or any pre-existing abrasions (Småge et al., 2018), and the pathology described from this study is consistent of the classical sign of tenacibaculosis (Toranzo et al., 2005).

4.5 Histopathological changes by *T. finnmarkense*

Challenge groups from Trial 2 and 3 were compared by their histological appearance after challenge with *T. finnmarkense*. Comparing the groups allows investigation of the effect of water quality and increased smolt size to the susceptibility to infection with *T. finnmarkense*. Samples from 1F were not included due to the low development of clinical disease signs and

mortality after challenge. An important note is that these comparisons are based on observations, and they were not measured for epidermis thickness and counting of mucous cells by the Aiforia® algorithm as the software has only been trained on normal histology samples.

The pathological findings were mirrored in the morphological analysis of histological sections, where the degree of histopathological changes was most severe in the jaw and ventral skin-samples. Loss of scales, loss, and degeneration of the epidermis, dilated blood, vessels and infiltration of immune cells was among frequent findings described in histological sections. These findings are in accordance with what has been observed from Atlantic salmon in field outbreaks and in challenge experiments with *T. finnmarkense* (Småge et al., 2017) as well as with *T. maritimum* (van Gelderen et al., 2011). In this study, the large variation between fish reared in the same water quality in terms of tissue damage and inflammatory response complicates the process of characterizing differences between water quality and smolt size. Most of the pathological changes observed in F fish are also observed in LSS and vice versa. However, a difference is observed in the degree of damage to the jaw epidermis, in which F fish had the poorest skin surface (Appendix 4). This finding suggests the transfer to seawater and challenge with *T. finnmarkense* is a greater load on fish reared in F compared to LSS.

Limited changes were observed in most control samples. However, there were control samples from all groups and both tissues (jaw and ventral) showing tissue damage and/or complete loss of epidermis, in addition to the infiltration of inflammatory cells. This damage is likely due to mechanical rupture as a result of the fish being in contact with the bottom of tanks and tank walls or handling when fish was transferred between tanks. However, damages to the tissue could also be a result of histological preparations, i.e. decalcification of sectioning, though this would not explain the immune response observed.

Welfare parameters and ulcer scoring were combined and used as help when investigating samples histologically (Appendix 4). In some fish, a strong correlation between scoring and histological appearance was observed, however, this was not consistent in all samples. This specific issue is not documented extensively in the literature. The disagreement between the methods could relate to that sampled skin areas are not representative of the status of the whole fish and vice versa. Also, the level of details attained from examining a histological section is greater compared to information attained by macroscopic examination.

The results from the histopathological analysis are further mirrored in gene expression analysis (Appendix 6), indicating increased blood supply to both the epidermis and the dermis as

indicated by the up-regulation of plasma and erythrocyte related genes. This, in addition to the down-regulation of tissue renewal genes in parallel with the up-regulation of cell stress and apoptosis related genes, is an indication of the skin dealing with stressful conditions. The virulence mechanisms of *T. finnmarkense* are not well studied. For *T. maritimum*, however, extracellular products (ECPs) (toxins and enzymes together) are suggested to take part in the pathogenesis of this bacterium infiltrating the skin of red (*Pagrus major*) and black sea bream (*Spondyliosoma cantharus*) in experiments (Baxa, Kawai, & Kusuda, 1988). ECPs as a part of the pathogenesis in *T. maritimum* is also suggested from experiments with Atlantic salmon where the bacterium causes ulcerative lesions in the skin (van Gelderen, Carson, & Nowak, 2009). The ECPs of *T. maritimum* have been shown capable of breaking down components like nucleases, amylases, and gelatin, due to their high proteolytic activity (Avendaño-Herrera et al., 2006). In addition, efficient uptake of iron is suggested as a virulence mechanism in *T. maritimum* (Avendaño-Herrera, Toranzo, Romalde, Lemos, & Magariños, 2005). The gene expression analysis also indicates up-regulation of host iron metabolism in this study which suggests a similar virulence mechanism for *T. finnmarkense*. Lastly, *T. maritimum* has the ability to adhere to hydrophobic components, like fish mucus (Magarinos, Pazos, Santos, Romalde, & Toranzo, 1995). As *T. maritimum* and *T. finnmarkense* are both from the same taxon, *Tenacibaculum*, and are associated with ulceration and skin lesions, *T. finnmarkense* may possess similar virulence mechanism as described for *T. maritimum*, including highly proteolytic ECPs and iron uptake mechanisms which allows the bacterium to break down host cells and compete with the hosts iron-binding proteins.

Loss of the physical barrier that protects the fish from the outer environment, results in loss of keratocytes, which have been shown to exert phagocytic activity including uptake of bacteria (Lindell et al., 2012). Keratocytes also possess adaptive immune functions (Holm et al., 2017). Lastly, removing the mucus layer may lead to increased infections, ulcer development, and mortality (Olsen et al., 2011; Svendsen & Bøggwald, 1997). The effect of the histopathological changes observed in the current trial could be associated with higher susceptibility to infections.

4.6 Immunohistochemistry and gene expression provide insights into the pathogenesis of *T. finnmarkense*

The results from immunohistochemistry verified the presence of *T. finnmarkense* and gave information on where the bacterium is located in the tissue during infection. *T. finnmarkense* was most frequently observed in connective tissue compartments of the skin. However, in heavily infected samples, the bacterium was observed in all layers of the skin, including subcutaneous connective tissue and the hypodermis. In the dense connective tissue, the bacterium was observed oriented between alternating collagen fibers. These findings are also reported from *T. finnmarkense* field outbreaks (Småge et al., 2017) in addition to experimentally induced tenacibaculosis using the same strain as in this thesis (Småge et al., 2018). Similar microscopic pathology in Atlantic salmon is reported also from other *Tenacibaculum* spp., including *T. dicentrarchi* (Avendaño-Herrera et al., 2016; Klakegg et al., 2019) and *Tenacibaculum* spp. (Olsen et al 2011). *Tenacibaculum* spp. associated with field outbreaks of winter ulcer disease (*M. viscosa*) appear to have an affinity for collagenous tissue (Olsen et al., 2011), similar to what is observed with *T. finnmarkense* in this study where the connective tissue compartments (anchoring points) seem to work as a transport pathway for the bacterium. The affinity for collagenous tissue is also reported of *T. maritimum* causing tenacibaculosis in farmed sole (*Solea senegalensis*) (Vilar et al., 2012). In some samples, *T. finnmarkense* was observed in the deep layers of the myocommata, close to the vent area. As ulceration in this area is common in tank experiments, and the skin is directly linked to this area through major connective tissue compartments, this area could be important for the development of infection. The bacterium was rarely observed in the epidermis in histological sections. This finding is also described by others (Olsen et al., 2011; Småge, 2018). A probable reason for this could be that the mucus layer is not preserved during histological preparations as suggested by Handler, Soltani, and Percival (1997). In SEM sections however, the bacterium is observed in the mucus layer on top of keratocytes (Småge, 2018), in similarity to *T. maritimum* field outbreak (Vilar et al., 2012). Gene expression data suggest similar effects from both the epidermis and the dermis, suggesting the bacterium was present in both tissue layers at sample points.

In this study, *T. finnmarkense* was observed gradually reduced in numbers from the center of the infection, as also described for tenacibaculosis caused by *T. finnmarkense* (Småge, 2018) and mouthrot caused by *T. maritimum* (Frisch, Småge, Vallestad, et al., 2018). Often, the separation between damaged and intact tissue was abrupt, suggesting a local infection. This is also reported from experimentally induced mouthrot cause by *T. maritimum* (Frisch, Småge,

Johansen, et al., 2018). In many samples, tissue damage and the presence of *T. finnmarkense* were observed together with inflammation. This again is reflected by the gene expression data where an extensive upregulation of immune-related genes is observed. Also, gene group associated with heme is up-regulated. This is mirrored in the histopathological changes observed, with dilated blood vessels in the connective tissue compartments of the skin which could be one way for *T. finnmarkense* to gain access to host iron sources.

The results from the microarray analysis must be seen in correlation to the histopathological changes observed and observations from immunohistochemistry. Within each tissue, a pattern was observed, indicating upregulating of immune genes, downregulating of cell renewal genes, upregulating of cell stress and apoptosis related genes, and downregulating of tissue renewal genes. This again could be an indication that immune genes are up-regulated at the expense of tissue renewal. Further, the gene expression analysis indicating a similar pattern of expression in both the epidermis and dermis is supported by the observation of histopathological changes and the presence of *T. finnmarkense* in both tissues. However, the similarity between tissues could also be explained by contamination of dermis in epidermis samples. Contradictions between histological analysis and gene expression could be explained by the different approaches for investigating the effect of infection with *T. finnmarkense*. The histological changes observed are a result of changes happening over a period of time, while gene expression is very fast-changing, and is the result of the state at that exact moment the tissue was sampled.

4.7 Methodical limitations

The following section includes considerations regarding histological techniques and the challenge experiment used in this thesis. Other methodical limitations are addressed in their appropriate section.

4.7.1 Histology

Methods used for histological analysis make up the majority of the methods used in this thesis. The process of preparing skin samples for histology consists of multiple different steps. All methods are not standardized, resulting in the need for discretionary assessments, which could alter results. Techniques are probably not optimized for every tissue type used in this study. The structure of skin tissue is dependent on body site (Kryvi & Poppe, 2016; Pittman et al., 2013), for example, the jaw tissue is devoid of scales, however, consists of teeth and bone in contrast to ventral and dorsal skin tissue. For the histological preparations in this study, the jaw

tissue was treated differently than dorsal and ventral skin tissue regarding decalcification. Decalcification medium has shown to affect the number of mucous cells (Pittman et al., 2013). The information retrieved from a sample may also vary depending on the embedding medium (Yeung, 1999), in addition to staining techniques and orientation of samples when sectioning (Pittman et al., 2013). As histological preparations are time-consuming and the number of samples in this study was relatively large, the preparations were performed in several different batches. Between each batch of samples prepared, new solutions (i.e. decalcification, staining) were made. Multiple preparations could have introduced minor artifacts, although strict compliance with the protocol was followed.

4.7.2 Experimental setup

An important limitation of this study is the number of fish used. The number was limited to a minimum due to welfare issues regarding challenge of fish to pathogens in accordance with the three R's in animal research (Flecknell, 2002). Also, the number of fish in the experiment was reduced after each of the samplings. Reducing the number of fish during the experiment could bias the results since there are fewer fish at the end of the experiment than it was at the start. For some of the analysis, no significant differences were observed in which could be explained by the sample size within groups may have been insufficient for some of the analysis (Charan & Kantharia, 2013). In addition, not all fish sampled were in all methods included for analysis due to economical limitations.

The experiment was a part of developing a challenge model for *T. finnmarkense*. Results from this study indicate that the number of fish should be increased if a similar study is done in the future. Alternatively, to limit the number of research animals, the number of sample points could be reduced.

One important discovery in this study was the lack of correlation between the welfare score and the histology or gene expression. The inconsistent correlation could be explained if the sample used for analysis was unrepresentative, as it is only a small part of the whole fish. It could, however, also be related to methodological inconsistencies as scoring was conducted by different persons throughout the experiment.

5 Conclusion and future perspectives

The aim of this study was, by using histological techniques, to investigate if two different rearing conditions, freshwater, and low strength seawater affected the skin surface morphology. Further, the goal was to characterize differences in the skin between water qualities in order to explain any differences in susceptibility of *T. finnmarkense*. Results from this study indicate that the skin developed differently for fish reared in LSS compared to F, with reversed development of epidermis thickness. Also, the degree of histopathological changes observed on the skin surface was more severe in F fish compared to LSS. This is also reflected in the prevalence of *T. finnmarkense* and mortality rates within the challenge groups. The transfer to full strength seawater is suggested to be a bigger burden for the skin of fish reared in F compared to LSS. Thus, the skin of LSS fish is in a better status to respond to a challenge with *T. finnmarkense*, suggesting a positive effect of salinity adaptation in 26 ppt before sea transfer when in the risk of developing tenacibaculosis. However, finding the right production protocol that balances salinity in order to maximize growth and survival without the cost of production disorders, would require more research.

Loss of epidermis and scales were observed in challenged and control fish of all groups in both water qualities, suggesting ulcers could develop in all groups independently of water quality. As F fish had a higher prevalence of *T. finnmarkense* and more severe histopathological changes, this indicates that fish reared in LSS can better respond to and eliminate the bacterium compared to fish reared in F, resulting in the prevention of developing disease. This further suggests that there could be structural, cellular, and/or humoral differences between the fish groups, that in this study was not detected by histology nor gene expression. The effect of the presence of *T. finnmarkense* and the damage the bacterium is inflicting to the host tissue is however demonstrated in gene expression data, suggesting the fish are compensating daily functions in order to combat the bacterium. Maintaining intact surface barriers including the epidermis and mucus layer should be of high importance, as rupture of the surface is most likely affecting several skin functions.

Although differences between water qualities are observed in this study it has been difficult to characterize exactly what is the structural difference between the skin of fish reared in freshwater compared to low strength seawater. This would be a highly interesting and important research area for future studies. Using strategies like brackish water RAS for production of

post-smolts, and at the same time limit the damage to skin surfaces could prevent infection with *T. finnmarkense* and therefore prevent the development of tenacibaculosis.

References

- Aunsmo, A., Bruheim, T., Sandberg, M., Skjerve, E., Romstad, S., & Larssen, R. (2008). Methods for investigating patterns of mortality and quantifying cause-specific mortality in sea-farmed Atlantic salmon *Salmo salar*. *Diseases of aquatic organisms*, *81*(2), 99-107.
- Avendaño-Herrera, R., Toranzo, A. E., & Magariños, B. (2006). Tenacibaculosis infection in marine fish caused by *Tenacibaculum maritimum*: a review. *Diseases of aquatic organisms*, *71*(3), 255-266.
- Avendaño-Herrera, R., Toranzo, A. E., Romalde, J. L., Lemos, M. L., & Magariños, B. (2005). Iron uptake mechanisms in the fish pathogen *Tenacibaculum maritimum*. *Appl. Environ. Microbiol.*, *71*(11), 6947-6953.
- Avendaño-Herrera, R., Irgang, R., Sandoval, C., Moreno-Lira, P., Houel, A., Duchaud, E., . . . Ilardi, P. (2016). Isolation, characterization and virulence potential of *Tenacibaculum dicentrarchi* in salmonid cultures in Chile. *Transboundary and emerging diseases*, *63*(2), 121-126.
- Baxa, D. V., Kawai, K., & Kusuda, R. (1988). In vitro and in vivo activities of *Flexibacter maritimus* toxins. *Bulletin of marine sciences and fisheries, Kochi University*(10), 1-8.
- Benediktsdóttir, E., Verdonck, L., Spröer, C., Helgason, S., & Swings, J. (2000). Characterization of *Vibrio viscosus* and *Vibrio wodanis* isolated at different geographical locations: a proposal for reclassification of *Vibrio viscosus* as *Moritella viscosa* comb. nov. *International Journal of Systematic and Evolutionary Microbiology*, *50*(2), 479-488.
- Benhamed, S., Guardiola, F. A., Mars, M., & Esteban, M. Á. (2014). Pathogen bacteria adhesion to skin mucus of fishes. *Veterinary microbiology*, *171*(1-2), 1-12.
- Bernardet, J.-F., Segers, P., Vancanneyt, M., Berthe, F., Kersters, K., & Vandamme, P. (1996). Cutting a Gordian knot: emended classification and description of the genus *Flavobacterium*, emended description of the family *Flavobacteriaceae*, and proposal of *Flavobacterium hydatis* nom. nov. (basonym, *Cytophaga aquatilis* Strohl and Tait 1978). *International Journal of Systematic and Evolutionary Microbiology*, *46*(1), 128-148.
- Bjornsdottir, B., Gudmundsdottir, T., & Gudmundsdottir, B. (2011). Virulence properties of *Moritella viscosa* extracellular products. *Journal of fish diseases*, *34*(5), 333-343.
- Bleie, H., & Skrudland, A. (2014). Tap av laksefisk i sjø. *Rapport fra Mattilsynet*.

- Boeuf, G., & Payan, P. (2001). How should salinity influence fish growth? *Comparative Biochemistry and Physiology Part C: Toxicology & Pharmacology*, 130(4), 411-423.
- Bornø, G., Sviland, C., Jensen, B., Tarpai, A., Garseth, Å., Skjelstad, H., . . . Nilsen, H. (2011). The health situation in farmed salmonids 2010. *Farmed Fish Health Report 2010*, 36.
- Bruno, D. W., Noguera, P. A., & Poppe, T. T. (2013). *A colour atlas of salmonid diseases* (Vol. 91): Springer Science & Business Media.
- Calabrese, S. (2017). Environmental and biological requirements of post-smolt Atlantic salmon (*Salmo salar* L.) in closed-containment aquaculture systems.
- Charan, J., & Kantharia, N. (2013). How to calculate sample size in animal studies? *Journal of pharmacology & pharmacotherapeutics*, 4(4), 303.
- Dietz, C., Stiller, K., Griese, M., Schulz, C., & Susenbeth, A. (2013). Influence of salinity on energy metabolism in juvenile turbot, *Psetta maxima* (L.). *Aquaculture Nutrition*, 19, 135-150.
- Duston, J. (1994). Effect of salinity on survival and growth of Atlantic salmon (*Salmo salar*) parr and smolts. *Aquaculture*, 121(1-3), 115-124.
- Elliott, D. (2011). THE SKIN| Functional morphology of the integumentary system in fishes.
- Erikson, U. G., Solvang, T., Schei, M., Ag, S., & Aalberg, K. (2018). *Hydrolicer-Utredning av system, stress og velferd ved avlusing* (8214068614). Retrieved from
- Esteban, M. Á. (2012). An overview of the immunological defenses in fish skin. *ISRN immunology*, 2012.
- Ferguson, H. W., Christian, M. D., Hay, S., Nicolson, J., Sutherland, D., & Crumlish, M. (2010). Jellyfish as vectors of bacterial disease for farmed salmon (*Salmo salar*). *Journal of veterinary diagnostic investigation*, 22(3), 376-382.
- Flecknell, P. (2002). Replacement, reduction, refinement. *ALTEX-alternatives to Animal Experimentation*, 19(2), 73-78.
- Fletcher, T. C., Jones, R., & Reid, L. (1976). Identification of glycoproteins in goblet cells of epidermis and gill of plaice (*Pleuronectes platessa* L.), flounder (*Platichthys flesus* (L.)) and rainbow trout (*Salmo gairdneri* Richardson). *The Histochemical Journal*, 8(6), 597-608.
- Frelier, P. (1994). Macroscopic and microscopic features of ulcerative stomatitis in farmed Atlantic salmon *Salmo salar*. *Dis. Aquat. Org.*, 18, 227-231.
- Frisch, K. (2018). *Mouthrot in farmed Atlantic salmon*. (Degree of Philosophiae Doctor), University of Bergen,

- Frisch, K., Småge, S. B., Johansen, R., Duesund, H., Brevik, Ø. J., & Nylund, A. (2018). Pathology of experimentally induced mouthrot caused by *Tenacibaculum maritimum* in Atlantic salmon smolts. *PloS one*, *13*(11), e0206951.
- Frisch, K., Småge, S. B., Vallestad, C., Duesund, H., Brevik, Ø. J., Klevan, A., . . . Brudeseth, B. (2018). Experimental induction of mouthrot in Atlantic salmon smolts using *Tenacibaculum maritimum* from Western Canada. *Journal of fish diseases*, *41*(8), 1247-1258.
- Garrod, D., & Chidgey, M. (2008). Desmosome structure, composition and function. *Biochimica et Biophysica Acta (BBA)-Biomembranes*, *1778*(3), 572-587.
- Grave, K., & Helgesen, K. O. (2018). *Rapport 5-2018: Forbruk av antibakterielle midler til oppdrettsfisk og rensefisk 2013-2017*. Retrieved from <https://www.vetinst.no/rapporter-og-publikasjoner/rapporter/2018/antibakterielle-midler-til-oppdrettsfisk-og-rensefisk--rekvireringer-forbruk-og-diagnoser-2013-2017>
- Gudding, R. (2010). *Vaksinasjon av dyr* (R. Gudding Ed.). Oslo: Scandinavian Veterinary Press.
- Habib, C., Houel, A., Lunazzi, A., Bernardet, J.-F., Olsen, A. B., Nilsen, H., . . . Duchaud, E. (2014). Multilocus sequence analysis of the marine bacterial genus *Tenacibaculum* suggests parallel evolution of fish pathogenicity and endemic colonization of aquaculture systems. *Appl. Environ. Microbiol.*, *80*(17), 5503-5514.
- Handeland, S. O., Berge, Å., Björnsson, B. T., & Stefansson, S. O. (1998). Effects of temperature and salinity on osmoregulation and growth of Atlantic salmon (*Salmo salar* L.) smolts in seawater. *Aquaculture*, *168*(1-4), 289-302.
- Handler, J., Soltani, M., & Percival, S. (1997). The pathology of *Flexibacter maritimus* in aquaculture species in Tasmania, Australia. *Journal of fish diseases*, *20*(3), 159-168.
- Hansen, G. H., Bergh, Ø., Michaelsen, J., & Knappskog, D. (1992). *Flexibacter ovolyticus* sp. nov., a pathogen of eggs and larvae of Atlantic halibut, *Hippoglossus hippoglossus* L. *International Journal of Systematic and Evolutionary Microbiology*, *42*(3), 451-458.
- Herbinger, C., & Friars, G. (1991). Correlation between condition factor and total lipid content in Atlantic salmon, *Salmo salar* L., parr. *Aquaculture Research*, *22*(4), 527-529.
- Hjeltnes, B., Bang-Jensen, B., Bornø, G., Haukaas, A., & Walde, C. S. (2019). *Fish Health Report 2018*. Retrieved from

- Hjerde, E., Karlsen, C., Sørum, H., Parkhill, J., Willassen, N. P., & Thomson, N. R. (2015). Co-cultivation and transcriptome sequencing of two co-existing fish pathogens *Moritella viscosa* and *Aliivibrio wodanis*. *BMC genomics*, *16*(1), 447.
- Holm, H. J., Skugor, S., Bjelland, A., Radunovic, S., Wadsworth, S., Koppang, E., & Evensen, Ø. (2017). Contrasting expression of immune genes in scaled and scaleless skin of Atlantic salmon infected with young stages of *Lepeophtheirus salmonis*. *Developmental & Comparative Immunology*, *67*, 153-165.
- Imslund, A. K., Foss, A., Gunnarsson, S., Berntssen, M. H., FitzGerald, R., Bonga, S. W., . . . Stefansson, S. O. (2001). The interaction of temperature and salinity on growth and food conversion in juvenile turbot (*Scophthalmus maximus*). *Aquaculture*, *198*(3-4), 353-367.
- Johansson, L.-H., Timmerhaus, G., Afanasyev, S., Jørgensen, S. M., & Krasnov, A. (2016). Smoltification and seawater transfer of Atlantic salmon (*Salmo salar* L.) is associated with systemic repression of the immune transcriptome. *Fish & shellfish immunology*, *58*, 33-41.
- Karlsen, C., Ellingsen, A. B., Wiik-Nielsen, C., Winther-Larsen, H. C., Colquhoun, D. J., & Sørum, H. (2014). Host specificity and clade dependent distribution of putative virulence genes in *Moritella viscosa*. *Microbial pathogenesis*, *77*, 53-65.
- Karlsen, C., Sørum, H., Willassen, N. P., & Åsbakk, K. (2012). *Moritella viscosa* bypasses Atlantic salmon epidermal keratocyte clearing activity and might use skin surfaces as a port of infection. *Veterinary microbiology*, *154*(3-4), 353-362.
- Karlsen, C., Vanberg, C., Mikkelsen, H., & Sørum, H. (2014). Co-infection of Atlantic salmon (*Salmo salar*), by *Moritella viscosa* and *Aliivibrio wodanis*, development of disease and host colonization. *Veterinary microbiology*, *171*(1-2), 112-121.
- Karlsen, C., Ytteborg, E., Timmerhaus, G., Høst, V., Handeland, S. O., Jørgensen, S. M., & Krasnov, A. (2018). Atlantic salmon skin barrier functions gradually enhance after seawater transfer. *Scientific reports*, *8*(1), 1-12.
- Klakegg, Ø., Abayneh, T., Fauske, A. K., Fülberth, M., & Sørum, H. (2019). An outbreak of acute disease and mortality in Atlantic salmon (*Salmo salar*) post-smolts in Norway caused by *Tenacibaculum dicentrarchi*. *Journal of fish diseases*, *42*(6), 789-807.
- Kryvi, H., & Poppe, T. (2016). *Fiskeanatomi*: Vigemostad & Bjørke AS.
- Lindell, K., Fahlgren, A., Hjerde, E., Willassen, N.-P., Fällman, M., & Milton, D. L. (2012). Lipopolysaccharide O-antigen prevents phagocytosis of *Vibrio anguillarum* by rainbow trout (*Oncorhynchus mykiss*) skin epithelial cells. *PloS one*, *7*(5).

- López, J., Núñez, S., Magariños, B., Castro, N., Navas, J., De La Herran, R., & Toranzo, A. (2009). First isolation of *Tenacibaculum maritimum* from wedge sole, *Dicologlossa cuneata* (Moreau). *Journal of fish diseases*, 32(7), 603-610.
- Lunder, T., Evensen, Ø., Holstad, G., & Håstein, T. (1995). 'Winter ulcer' in the Atlantic salmon *Salmo salar*. Pathological and bacteriological investigations and transmission experiments. *Diseases of aquatic organisms*, 23(1), 39-49.
- Magarinos, B., Pazos, F., Santos, Y., Romalde, J. L., & Toranzo, A. E. (1995). Response of *Pasteurella piscicida* and *Flexibacter maritimus* to skin mucus of marine fish. *Diseases of aquatic organisms*, 21(2), 103-108.
- Markestad, A., & Grave, K. (1997). Reduction of antibacterial drug use in Norwegian fish farming due to vaccination. *Developments in biological standardization*, 90, 365-369.
- Masumura, K., & Wakabayashi, H. (1977). An outbreak of gliding bacterial disease in hatchery-born red seabream (*Pagrus major*) and gilthead (*Acanthopagrus schlegeli*) fry in Hiroshima. *Fish Pathology*, 12(3), 171-177.
- McBride, M. J. (2014). The family flavobacteriaceae. *The Prokaryotes: Other Major Lineages of Bacteria and The Archaea*, 643-676.
- Morgan, J. D., & Iwama, G. K. (1991). Effects of salinity on growth, metabolism, and ion regulation in juvenile rainbow and steelhead trout (*Oncorhynchus mykiss*) and fall chinook salmon (*Oncorhynchus tshawytscha*). *Canadian journal of fisheries and aquatic sciences*, 48(11), 2083-2094.
- Noble, C., Gismervik, K., Iversen, M. H., Kolarevic, J., Nilsson, J., Stien, L. H., & Turnbull, J. F. (2018). Welfare Indicators for farmed Atlantic salmon: tools for assessing fish welfare.
- Olsen, A. B., Nilsen, H., Sandlund, N., Mikkelsen, H., Sørum, H., & Colquhoun, D. (2011). *Tenacibaculum* sp. associated with winter ulcers in sea-reared Atlantic salmon *Salmo salar*. *Diseases of aquatic organisms*, 94(3), 189-199.
- PHARMAQ-Analytiq. (2017). Ny analyse for påvisning av *Tenacibaculum maritimum*. Retrieved from <https://www.pharmaq.no/newsletter/stories/ny-analyse-for-/>
- Pineiro-Vidal, M., Carballas, C. G., Gomez-Barreiro, O., Riaza, A., & Santos, Y. (2008). *Tenacibaculum soleae* sp. nov., isolated from diseased sole (*Solea senegalensis* Kaup). *International Journal of Systematic and Evolutionary Microbiology*, 58(4), 881-885.
- Piñeiro-Vidal, M., Gijón, D., Zarza, C., & Santos, Y. (2012). *Tenacibaculum dicentrarchi* sp. nov., a marine bacterium of the family Flavobacteriaceae isolated from European sea

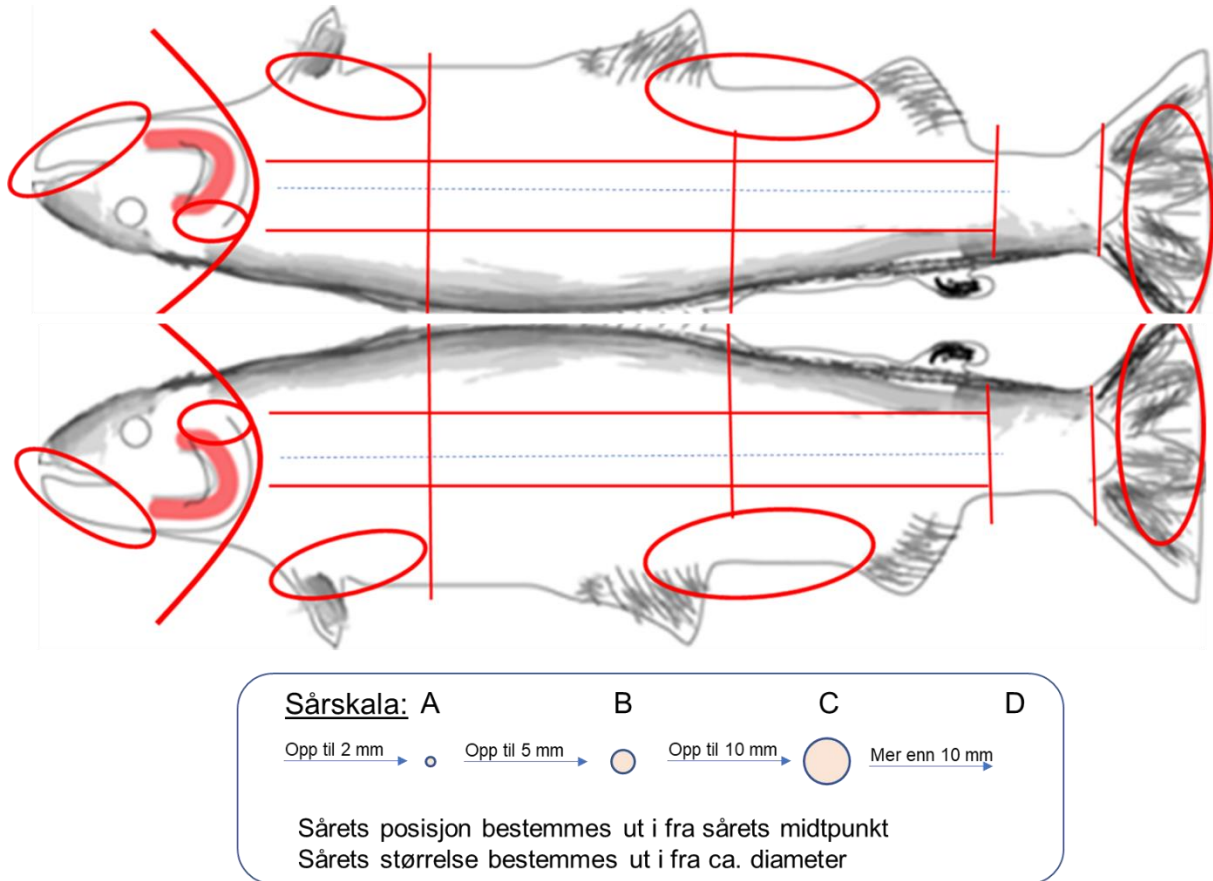
- bass. *International Journal of Systematic and Evolutionary Microbiology*, 62(2), 425-429.
- Pineiro-Vidal, M., Riaza, A., & Santos, Y. (2008). *Tenacibaculum discolor* sp. nov. and *Tenacibaculum gallaicum* sp. nov., isolated from sole (*Solea senegalensis*) and turbot (*Psetta maxima*) culture systems. *International Journal of Systematic and Evolutionary Microbiology*, 58(1), 21-25.
- Pittman, K., Pittman, A., Karlson, S., Cieplinska, T., Sourd, P., Redmond, K., . . . Sweetman, E. (2013). Body site matters: an evaluation and application of a novel histological methodology on the quantification of mucous cells in the skin of Atlantic salmon, *Salmo salar* L. *Journal of fish diseases*, 36(2), 115-127.
- Quilhac, A., & Sire, J. Y. (1999). Spreading, proliferation, and differentiation of the epidermis after wounding a cichlid fish, *Hemichromis bimaculatus*. *The Anatomical Record: An Official Publication of the American Association of Anatomists*, 254(3), 435-451.
- Roberts, R. J., & Ellis, A. (2012). The anatomy and physiology of teleosts. *Fish Pathology*, 17-61.
- Shephard, K. L. (1994). Functions for fish mucus. *Reviews in fish biology and fisheries*, 4(4), 401-429.
- Sire, J.-Y. (1989). The same cell lineage is involved in scale formation and regeneration in the teleost fish *Hemichromis bimaculatus*. *Tissue and Cell*, 21(3), 447-462.
- Småge, S. B. (2018). *Tenacibaculosis in Norwegian farmed Atlantic salmon*. (Degree of Philosophiae Doctor), University of Bergen, Bergen. Retrieved from <http://bora.uib.no/handle/1956/19440>
- Småge, S. B., Brevik, Ø. J., Duesund, H., Ottem, K. F., Watanabe, K., & Nylund, A. (2016). *Tenacibaculum finnmarkense* sp. nov., a fish pathogenic bacterium of the family Flavobacteriaceae isolated from Atlantic salmon. *Antonie Van Leeuwenhoek*, 109(2), 273-285.
- Småge, S. B., Brevik, Ø. J., Frisch, K., Watanabe, K., Duesund, H., & Nylund, A. (2017). Concurrent jellyfish blooms and tenacibaculosis outbreaks in Northern Norwegian Atlantic salmon (*Salmo salar*) farms. *PloS one*, 12(11), e0187476.
- Småge, S. B., Frisch, K., Brevik, Ø. J., Watanabe, K., & Nylund, A. (2016). First isolation, identification and characterisation of *Tenacibaculum maritimum* in Norway, isolated from diseased farmed sea lice cleaner fish *Cyclopterus lumpus* L. *Aquaculture*, 464, 178-184.

- Småge, S. B., Frisch, K., Vold, V., Duesund, H., Brevik, Ø. J., Olsen, R. H., . . . Watanabe, K. (2018). Induction of tenacibaculosis in Atlantic salmon smolts using *Tenacibaculum finnmarkense* and the evaluation of a whole cell inactivated vaccine. *Aquaculture*, 495, 858-864.
- Solheim, K. (2020). *The effect of using different salinities in smolt production on the susceptibility to tenacibaculosis in Atlantic salmon after sea water transfer*. (Master's degree), University of Bergen, Bergen.
- Soltani, M., & Burke, C. (1995). Responses of fish-pathogenic *Cytophaga/Flexibacter*-like bacteria (CFLB) to environmental conditions. *Bulletin of the European Association of Fish Pathologists (United Kingdom)*.
- Soltani, M., Munday, B., & Burke, C. (1996). The relative susceptibility of fish to infections by *Flexibacter columnaris* and *Flexibacter maritimus*. *Aquaculture*, 140(3), 259-264.
- Sommerset, I., Krossøy, B., Biering, E., & Frost, P. (2005). Vaccines for fish in aquaculture. *Expert review of vaccines*, 4(1), 89-101.
- Sommerset, I., Walde, C. S., Bang Jensen, B., Bornø, G., Haukaas, A., & Brun, E. r. (2020). *Fiskehelserapporten 2019*. Retrieved from Statistics-Norway. (2019). Aquaculture Retrieved from <https://www.ssb.no/en/jord-skog-jakt-og-fiskeri/statistikker/fiskeoppdrett/aar>
- Suzuki, M., Nakagawa, Y., Harayama, S., & Yamamoto, S. (2001). Phylogenetic analysis and taxonomic study of marine *Cytophaga*-like bacteria: proposal for *Tenacibaculum* gen. nov. with *Tenacibaculum maritimum* comb. nov. and *Tenacibaculum ovolyticum* comb. nov., and description of *Tenacibaculum mesophilum* sp. nov. and *Tenacibaculum amylolyticum* sp. nov. *International Journal of Systematic and Evolutionary Microbiology*, 51(5), 1639-1652.
- Sveen, L., Karlsen, C., & Ytteborg, E. (2020). Mechanical induced wounds in fish—a review on models and healing mechanisms. *Reviews in Aquaculture*.
- Svendsen, Y. S., & Bøgwald, J. (1997). Influence of artificial wound and non-intact mucus layer on mortality of Atlantic salmon (*Salmo salar*L.) following a bath challenge with *Vibrio anguillarum* and *Aeromonas salmonicida*. *Fish & shellfish immunology*, 7(5), 317-325.
- Takle, H. R., Ytteborg, E., Nielsen, K. V., Karlsen, C. R., Nilsen, H. K., Sveen, L., . . . Nilsen, A. (2015). *Sårproblematikk og hudhelse i laks-og regnbueørrettoppdrett* (8282962600). Retrieved from

- Toranzo, A. E., Magariños, B., & Romalde, J. L. (2005). A review of the main bacterial fish diseases in mariculture systems. *Aquaculture*, 246(1-4), 37-61.
- Tunnsjø, H. S., Paulsen, S. M., Mikkelsen, H., L'Abée-Lund, T. M., Skjerve, E., & Sørum, H. (2007). Adaptive response to environmental changes in the fish pathogen *Moritella viscosa*. *Research in microbiology*, 158(3), 244-250.
- van Gelderen, R., Carson, J., & Nowak, B. (2009). Effect of extracellular products of *Tenacibaculum maritimum* in Atlantic salmon, *Salmo salar* L. *Journal of fish diseases*, 32(8), 727-731.
- van Gelderen, R., Carson, J., & Nowak, B. (2011). Experimentally induced marine flexibacteriosis in Atlantic salmon smolts *Salmo salar*. II. Pathology. *Diseases of aquatic organisms*, 95(2), 125-135.
- Vilar, P., Faílde, L., Bermudez, R., Vigliano, F., Rianza, A., Silva, R., . . . Quiroga, M. (2012). Morphopathological features of a severe ulcerative disease outbreak associated with *Tenacibaculum maritimum* in cultivated sole, *Solea senegalensis* (L.). *Journal of fish diseases*, 35(6), 437-445.
- Wakabayashi, H., Hikida, M., & Masumura, K. (1986). *Flexibacter maritimus* sp. nov., a pathogen of marine fishes. *International Journal of Systematic and Evolutionary Microbiology*, 36(3), 396-398.
- Yeung, E. C. (1999). The use of histology in the study of plant tissue culture systems—some practical comments. *In Vitro Cellular & Developmental Biology-Plant*, 35(2), 137-143.
- Ytrestøyl, T., Takle, H., Kolarevic, J., Calabrese, S., Timmerhaus, G., Nilsen, T. O., . . . Terjesen, B. F. (2015). *Atlantic salmon post-smolts in RAS: effects of salinity, exercise and timing of seawater transfer on performance, physiology and welfare*. Paper presented at the 3rd Workshop on Recirculating Aquaculture Systems, Molde, Norway.
- Ytrestøyl, T., Takle, H., Kolarevic, J., Calabrese, S., Timmerhaus, G., Rosseland, B. O., . . . Stefansson, S. O. (2020). Performance and welfare of Atlantic salmon, *Salmo salar* L. post-smolts in recirculating aquaculture systems: Importance of salinity and water velocity. *Journal of the World Aquaculture Society*, 51(2), 373-392.

Appendix

Appendix 1 – Scoring schemes



The scoring scheme used for fish sampled 3 days post challenge. By Christian René Karlsen.

FISHWELL Morphological Operational Welfare Indicators (OWI's) for farmed Atlantic salmon v1.1

Level 0: Little or no evidence of this OWI, i.e. normal (not illustrated).

Level 1, minor to Level 3, clear evidence of the OWI.

	Eye haemorrhaging	Exophthalmia	Opercular damage	Snout damage	Upper jaw deformity	Lower jaw deformity	Emaciation
1	 Minor haemorrhages	 Eye protruding a little	 Operculum only partly covering gills	 Minor wound on snout (either jaw)	 Suspected malformation	 Suspected malformation	 Potentially emaciated
2	 Larger haemorrhages, or traumatic injury	 Moderate eye protrusion	 Operculum absent on one of the gills (gill exposed)	 Moderate wound and broken skin on snout	 Distinct malformation	 Distinct malformation	 Emaciated
3	 Large haemorrhages / traumatic injury. Eye may be ruptured	 Major eye protrusion	 Both opercula absent (both gills exposed)	 Large deep and extensive wound. Can cover the whole head	 Major malformation, jaw pointing backwards	 Major malformation, jaw pointing backwards	 Extremely emaciated






















	Vertebral deformity	Skin haemorrhages	Lesions / wounds ^{a,b}	Scale loss	Sea lice infection	Healed fin damage	Active fin damage ^c
1	 Signs of deformed spine	 Minor haemorrhaging, often on the belly of the fish	 One small wound (< 10 pence piece) ^a , subcutaneous tissue intact (no muscle visible)	 Loss of individual scales	 Light infection	 Most of the fin remaining	 Most of the fin remaining
2	 Clearly visible spinal deformity (e.g. short tail)	 Large area of haemorrhaging, often coupled with scale loss	 Several small wounds	 Small areas of scale loss (< 10% of the fish)	 0.05 - 0.08 pre-adult or adult lice cm ² of fish skin	 Half of the fin remaining	 Half of the fin remaining
3	 Extreme deformity	 Significant bleeding, often with severe scale loss, wounds and skin edema	 Large, severe wounds, muscle often exposed (≥ 10 pence piece)	 Large areas of scale loss (≥ 10% of the fish)	 ≥ 0.08 pre-adult or adult lice cm ² of fish skin	 Very little of the fin remaining	 Very little of the fin remaining

Figure: C. Noble, D. Izquierdo-Gomez, L. H. Sten, J. F. Turnbull, K. Gismervik, J. Nilsson. Photos: K. Gismervik, L. H. Sten, J. Nilsson, C. Noble, J. F. Turnbull, P. A. Sæther, I. K. Nerbovik, I. Simion, B. Torset, B. Klakegg, R. Andersen, C. Karlsen, K. J. Merok, F. Gregersen

^a For pre-smolts "one small wound" should be < 1 cm.

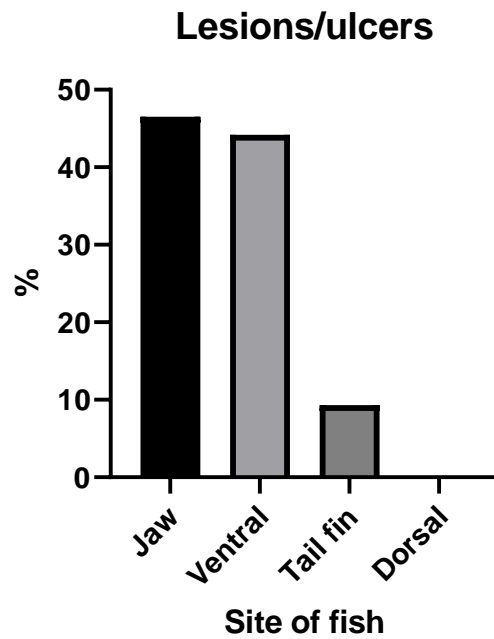
^b NB! Wounds that penetrate the abdominal cavity should be scored as a 3) irrespective of size

^c Splitting and/or haemorrhaging

(Noble et al., 2018).

Appendix 2 – Challenge experiment

A



B

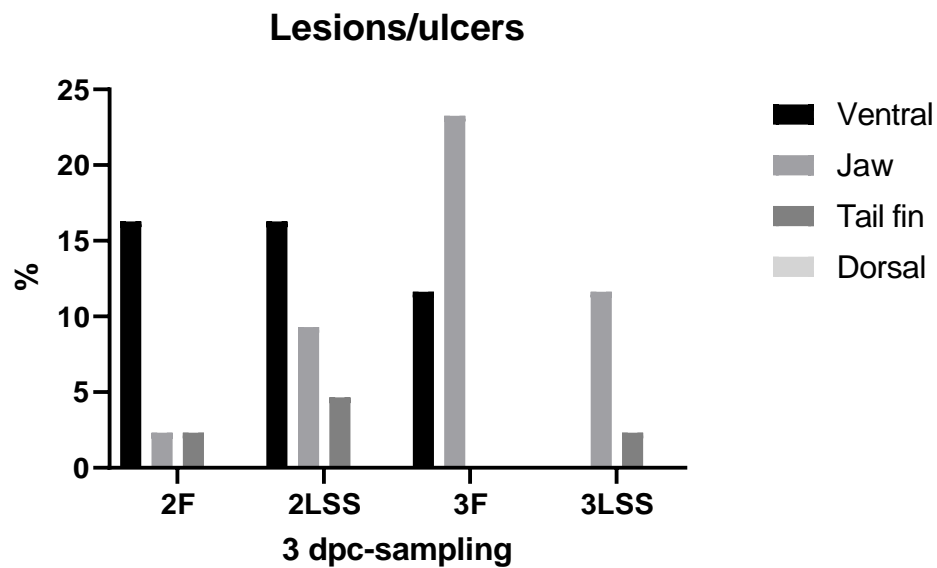


Figure 20. Percentage distribution of lesions or ulcers at different sites from Atlantic salmon smolts sampled 3 days post challenge (3 dpc). **A.** Distribution of lesions or ulcers to different sites of the fish. **B.** Comparison of Trial 2 (2F & 2LSS) and Trial 3 (3F & 3LSS).

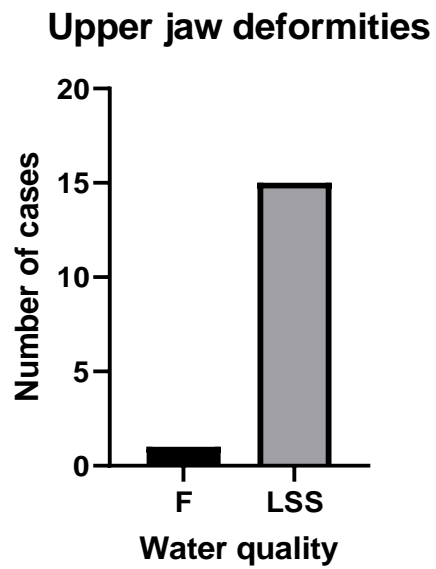


Figure 21. The number of cases of upper jaw deformities from all sampled Atlantic salmon smolts during the experiment, showing the differences between water qualities, freshwater (F), and low strength seawater (LSS).

Appendix 3 – Morphology and histological measurements of jaw 0-samples

Table 5. Histological measurements of Atlantic salmon jaw epidermis from 0-sampling 1, 2, and 3, showing the area (um²), thickness (um), number of mucous cells, and morphological score from fish reared in freshwater (F). The average thickness is based on six measurements. Comments from measurements, and welfare and ulcer score are also included.

WQ	Date	Sample	Area	Area (um ²)	Avg. thk (um)	McU	MCs	MC tot	MC purple	Epithelium	Comments	Welfare/ulcer score
F	15. mai 2019	k1	1	53291,54	51,88166667	10	6	16	1	2,00		
F	15. mai 2019	k1	2	55839,32	56,38666667	6	6	12	0	2,00		
F	15. mai 2019	k1	3	56697,39	76,78166667	5	3	8	0	3,00		
F	15. mai 2019	k2	1	46601,65	43,01	1	0	1	0	0,50		
F	15. mai 2019	k2	2	58318,77	60,6	11	2	13	0	1,00		
F	15. mai 2019	k2	3	51931,79	60,425	10	4	14	0	3,00		
F	15. mai 2019	k3	1	41133,07	25,46666667	1	1	2	0	3,00	Mye av epidermis borte	
F	15. mai 2019	k3	2	55816,33	64,06333333	7	0	7	0	1,50		
F	15. mai 2019	k3	3	54553,37	63,105	7	1	8	0	1,50	Antydning til cellearmar.	
F	15. mai 2019	k7	1	101142,7	131,52	0	0	0	0	1,00	Cellearmar	
F	15. mai 2019	k7	2	21904,94	21,75166667	0	0	0	0	3,00	Epidermis helt borte	
F	15. mai 2019	k7	3	18997,22	21,405	1	1	2	0	3,00	Nesten bare høye basale epitelceller igjen	
F	15. mai 2019	k8	1	98414,82	157,98333333	0	0	0	0	3,00	Cellearmar. Har ikke med 28,7 og 29 i med i gjennomsnittet.	
F	15. mai 2019	k8	2	56554	50,43833333	1	0	1	0	3,00		
F	15. mai 2019	k8	3	13707,34	17,21833333	0	0	0	0	3,00	Nesten bare høye basale epitelceller igjen. Tar denne ut av målingene.	
F	15. mai 2019	k9	1	153348,32	120,77	0	0	0	0	0,50		
F	15. mai 2019	k9	2	98502,71	86,77	3	0	3	2	1,00		
F	15. mai 2019	k9	3	70675	48,65333333	4	3	7	0	1,50		
F	11. juni 2019	k1	1	0	0	0	0	0	0	3,00	Epidermis helt borte.	Snuteskade
F	11. juni 2019	k1	2	30027,87	31,60333333	0	0	0	0	3,00	Epidermis nesten helt borte.	Snuteskade
F	11. juni 2019	k1	3	70559,3	40,04333333	4	1	5	0	2,00		Snuteskade
F	11. juni 2019	k2	1	139920,91	94,36833333	1	2	3	0	1,00		
F	11. juni 2019	k2	2	76382,74	51,36	8	1	9	0	1,50		
F	11. juni 2019	k2	3	42265,09	39,065	3	2	5	0	2,00		
F	11. juni 2019	k3	1	223158,14	138,8616667	0	0	0	0	1,50	Nekrose langs kanten?	
F	11. juni 2019	k3	2	193996,98	128,655	10	2	12	0	2,50	Nekrose langs kanten?	
F	11. juni 2019	k3	3	88890,74	56,17166667	7	1	8	0	0,50		
F	11. juni 2019	k7	1	247270,74	182,2116667	0	0	0	0	0,50	Epitelcellene er kantete med mellomrom, og cellearmar.	
F	11. juni 2019	k7	2	171628,08	94,45333333	0	0	0	0	1,00		
F	11. juni 2019	k7	3	106864,28	63,79833333	3	1	4	0	3,00		
F	11. juni 2019	k8	1	126855,98	85,87333333	23	2	25	1	0,50	Kjeven er snittet litt rart, men inkluderer den i resultatene.	
F	11. juni 2019	k8	2	84924,41	64,98166667	23	1	24	0	1,00	Kjeven er snittet litt rart, men inkluderer den i resultatene.	
F	11. juni 2019	k8	3	53173,3	45,02333333	12	0	12	0	1,00	Kjeven er snittet litt rart, men inkluderer den i resultatene.	
F	11. juni 2019	k9	1	248879,3	223,51	1	0	1	1	2,00	Stort "hull" i epidermis. Måler rundt hullet.	
F	11. juni 2019	k9	2	240802,1	153,9283333	18	0	18	0	2,00		
F	11. juni 2019	k9	3	97923,81	70,31666667	12	5	17	0	1,50		
F	5. juli 2019	k1	1	117,1083333	0	0	0	0	0	0,50		
F	5. juli 2019	k1	2	136593,68	93,40666667	17	0	17	0	0,50		
F	5. juli 2019	k1	3	84094,54	64,29333333	12	0	12	0	1,00		
F	5. juli 2019	k2	1	151648,95	156,2983333	0	0	0	0	0,50		
F	5. juli 2019	k2	2	83159,51	49,64333333	1	0	1	0	3,00	Nesten bare høye basale epitelceller igjen.	
F	5. juli 2019	k2	3	77477,93	55,61333333	6	0	6	0	2,50	Nekrose? Hullete epitel.	
F	5. juli 2019	k3	1	308238,77	206,175	1	0	1	0	2,50	Kantete celler	
F	5. juli 2019	k3	2	277065,93	166,8883333	76	3	79	0	2,50	Nekrose? Hullete epitel.	
F	5. juli 2019	k3	3	145355,96	97,005	35	3	38	0	1,50	Små kompakte kjerner i basale epitelceller.	
F	5. juli 2019	k7	1	625146,22	303,37	4	0	4	0	0,50		
F	5. juli 2019	k7	2	469334,96	198,5283333	40	5	45	0	2,00		
F	5. juli 2019	k7	3	205575	109,2983333	23	5	28	0	1,50		
F	5. juli 2019	k8	1	507876,81	331,005	0	0	0	0	1,50		
F	5. juli 2019	k8	2	266158,35	248,5333333	54	2	56	4	1,50		
F	5. juli 2019	k8	3	118848,76	78,63166667	25	2	27	0	1,50		
F	5. juli 2019	k9	1	332644,63	160,66	1	0	1	0	2,00		
F	5. juli 2019	k9	2	196957,54	117,3416667	10	0	10	0	2,00		
F	5. juli 2019	k9	3	115583,38	79,2	3	0	3	0	1,50		

Table 6. Histological measurements of Atlantic salmon jaw epidermis from 0-sampling 1, 2, and 3, showing the area (um²), thickness (um), number of mucous cells, and morphological score from fish reared in low strength seawater 26 ppt (LSS). The average thickness is based on six measurements. Comments from measurements, and welfare and ulcer score are also included.

WQ	Date	Sample	Area	Area (um ²)	Avg. thk (um)	Mc	MCs	MC tot	MC purple	Epithelium	Comments	Welfare/ulcer score
LSS	11. juni 2019	k1	1	341555,39	220,7966667	0	0	0	0	1,50	Nekroser?	
LSS	11. juni 2019	k1	2	264643,02	174,725	1	0	1	0	2,00	Epitelet revner basalt. Nekroser på overflaten?	
LSS	11. juni 2019	k1	3	92588,96	50,03666667	1	0	1	0	3,00	Basale høye epitelceller får rund kjerne der hvor epitelet er revnet/løstnet. Inkluderer ikke denne i resultatene.	
LSS	11. juni 2019	k2	1	188081,83	136,1816667	0	0	0	0	1,50	Nekroser?	mopsehode
LSS	11. juni 2019	k2	2	114801,9	76,96833333	9	0	9	0	2,00	Nekroser?	mopsehode
LSS	11. juni 2019	k2	3	118519,55	59,94666667	31	3	34	0	3,00	Tre turkise mucusceller, rett utenfor sidelinjekanalene.	mopsehode
LSS	11. juni 2019	k3	1	68046,82	194,6816667	0	0	0	0	1,00	Mye av kjevetuppen er borte. Nekrose (?) langs kanten.	
LSS	11. juni 2019	k3	2	37702,07	37,76	0	0	0	0	3,00	Epidermis mangler helt i område 2. Inkluderer ikke i resultatene.	
LSS	11. juni 2019	k3	3	93314,81	74,43	10	0	10	0	2,00		
LSS	11. juni 2019	k7	1	242684,61	192,3566667	0	0	0	0	2,00	Cellearmar på tuppen.	
LSS	11. juni 2019	k7	2	369819,87	202,62	1	0	1	1	1,50		
LSS	11. juni 2019	k7	3	117616,14	75,52166667	0	0	0	0	1,00		
LSS	11. juni 2019	k8	1	142968,46	159,565	0	0	0	0	1,00	Epidermis er løstnet fra kjevetuppen, men måler tykkelsen likevel. Antydning til cellearmar.	mopsehode
LSS	11. juni 2019	k8	2	124411,83	72,82	8	0	8	0	2,00		mopsehode
LSS	11. juni 2019	k8	3	86624,94	54,83666667	5	0	5	0	2,00		mopsehode
LSS	11. juni 2019	k9	1	294631,77	194,8633333	0	0	0	0	1,00	Cellearmar.	
LSS	11. juni 2019	k9	2	338069,65	159,94	1	0	1	0	1,00	Områder med cellearmar/vakuoler.	
LSS	11. juni 2019	k9	3	208438,8	100,8566667	12	0	12	0	2,00		
LSS	5. juli 2019	k1	1	323432,36	217,6166667	2	0	2	0	1,00	Mye pigment. Fin epitelkant, men nekroser under?	mopsehode
LSS	5. juli 2019	k1	2	256733,47	146,8166667	4	1	5	0	1,50		mopsehode
LSS	5. juli 2019	k1	3	131264,3	79,15	14	0	14	0	2,00	Mye av epitelet er ødelagt. Mye av epitelkanten er borte lengre bak.	mopsehode
LSS	5. juli 2019	k2	1		112,3916667	2	0	2	0	2,00		
LSS	5. juli 2019	k2	2	103217,88	58,90666667	7	2	9	0	2,00	Mye av epitelet ødelagt, og med vakuoler. Antydning til cellearmar, men ikke helt.	
LSS	5. juli 2019	k2	3	48103,01	27,55833333	2	0	2	0	2,50	Epitel ødelagt hele veien.	
LSS	5. juli 2019	k3	1	256131,83	151,2733333	1	0	1	0	2,00	Cellearmar helt på tuppen.	
LSS	5. juli 2019	k3	2	267354,77	106,275	39	2	41	0	2,50		
LSS	5. juli 2019	k3	3	146663,76	69,25833333	30	0	30	0	2,50		
LSS	5. juli 2019	k7	1	225315,25	160,1383333	1	0	1	0	2,00	Antydning til cellearmar. Lag med kompakte celler rett over basale epitelceller.	
LSS	5. juli 2019	k7	2	227688,39	117,5083333	53	0	53	0	2,00		
LSS	5. juli 2019	k7	3	245951,51	144,5666667	66	2	68	0	2,00		
LSS	5. juli 2019	k8	1	375803,86	221,9833333	0	0	0	0	2,50	Uklar orientering. Cellearmar på det som trolig er tuppen.	
LSS	5. juli 2019	k8	2	263600,03	141,4583333	0	0	0	0	2,00	Nekroser?	
LSS	5. juli 2019	k8	3	212090,73	121,5916667	14	1	15	0	1,00	Uklar orientering.	
LSS	5. juli 2019	k9	1	232641,45	167,705	0	0	0	0	1,50	Uklar orientering.	
LSS	5. juli 2019	k9	2	142347,52	86,78833333	11	0	11	0	2,00	Cellearmar på tuppen.	
LSS	5. juli 2019	k9	3	130054,55	77,44833333	12	0	12	0	2,00	Nekroser under epitelkant.	

Appendix 4 – Morphology and histological measurements of jaw 3 dpc-samples

Epidermis morphology

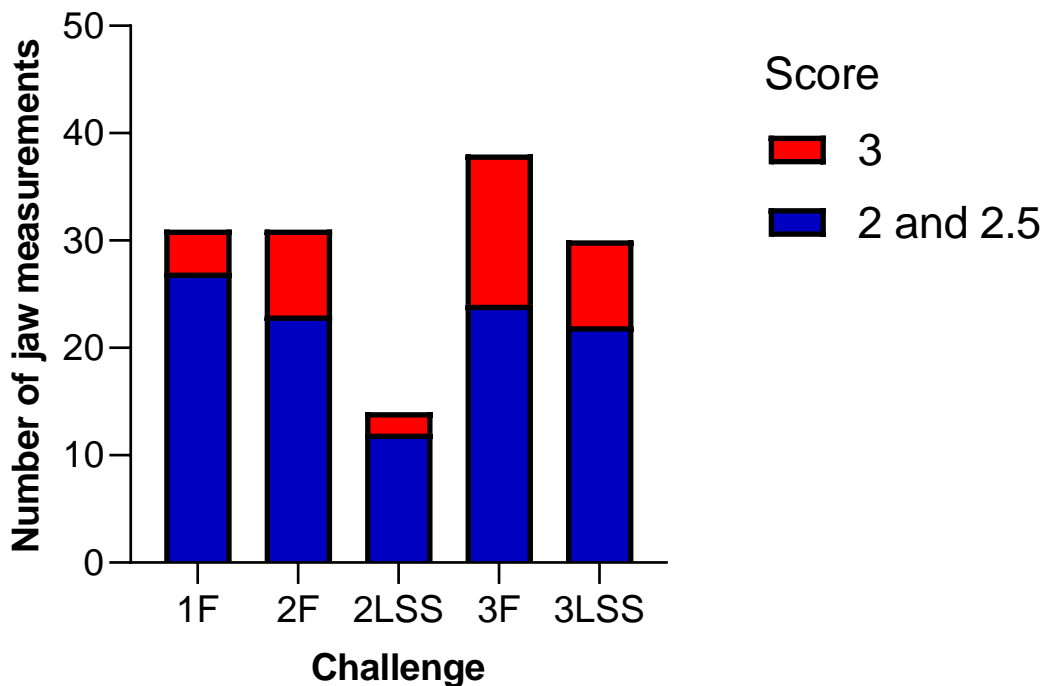


Figure 22. Atlantic salmon jaw epidermis morphology after transfer to full strength seawater and challenge with *T. finnmarkense*. Morphological score ranging from 0-3 is based on histological appearance of the epidermis as described in materials and methods section 2.5.4. The graph shows the number of jaw measurements (Area 1, 2 and 3) from each group (challenged and controls) with score 2 and 2.5 (serious to severe damage to the epidermis) and 3 (destroyed or missing epidermis). For complete scoring, see Table 7 - 11.

Table 7. Histological measurements of Atlantic salmon jaw epidermis from 3dpc-samples, showing the area (um²), thickness (um), number of mucous cells, and morphological score from fish in challenge 1F. The average thickness is based on six measurements. Comments from measurements, and welfare and ulcer score are also included.

Challenge	Date	Sample	Area	Area (um ²)	Avg. thk. (um)	Mcu	MCS	MC tot	MC purple	Epithelium	PP	Bas ept.	Bacteria	Comments	Welfare/ulcer score
1F	27. mai 2019	1a-1	1	204941,51	119,37	1	0	1	0	1,00	Nei		Nei		
1F	27. mai 2019	1a-1	2	215184,45	99,725	3	0	3	0	1,00	Nei		Nei		
1F	27. mai 2019	1a-1	3	121983,35	57,18166667	3	1	4	1	2,00	Antydning		Nei		
1F	27. mai 2019	1a-2	1	123919,68	76,85	3	1	4	0	3,00				Epidermis mangler i store deler av område 1. Mye bet.celler	Snuteskade
1F	27. mai 2019	1a-2	2	262548,41	151,1333333	17	2	19	4	1,00	Antydning				Snuteskade
1F	27. mai 2019	1a-2	3	257362,42	119,295	33	5	38	0	1,00					snuteskade
1F	27. mai 2019	2a-1	1	260291,73	190,2716667	1	0	1	0	2,00					
1F	27. mai 2019	2a-1	2	324037,04	209,5133333	2	0	2	0	2,00					
1F	27. mai 2019	2a-1	3	303232,88	191,3766667	23	0	23	0	1,50					
1F	27. mai 2019	2a-2	1	217593,41	135,945	1	0	1	0	2,50	Antydning	1	Nei	Vakuoler.	
1F	27. mai 2019	2a-2	2	329469,94	163,0616667	9	1	10	0	2,50	Ja	1	Nei	Vakuoler.	
1F	27. mai 2019	2a-2	3	138343,21	85,01166667	8	0	8	0	2,00	Ja	1			
1F	27. mai 2019	3a-1	1	183937,06	162,3233333	3	0	0	0	1,00	Ja	1			
1F	27. mai 2019	3a-1	2	339642,77	149,1466667	0	0	0	0	2,50	Ja	1			
1F	27. mai 2019	3a-1	3	211596,35	98,58666667	6	0	6	0	2,50	Ja	1			
1F	27. mai 2019	3a-2	1	253279,36	219,1483333	4	0	4	0	2,00					
1F	27. mai 2019	3a-2	2	266759,61	157,8633333	9	0	9	0	2,00	Ja				
1F	27. mai 2019	3a-2	3	191763,29	162,7666667	11	0	11	0	2,00					
1F	27. mai 2019	K1	1	338812,14	217,6916667	0	0	0	0	1,50	Ja	1			
1F	27. mai 2019	K1	2	425371,14	221,5433333	8	0	8	0	2,00	Antydning	1			
1F	27. mai 2019	K1	3	392691,48	185,6416667	12	0	12	1	2,50		1		Huller basalt i epidermis.	
1F	27. mai 2019	K2	1	382630,41	181,5483333	10	0	10	0	3,00				Epidermis er løsnet store deler av område 1.	
1F	27. mai 2019	K2	2	270649,48	149,7716667	7	1	8	1	2,50	Antydning				
1F	27. mai 2019	K2	3	237399,3	123,3266667	15	1	16	0	2,50					
1F	27. mai 2019	K3	1	56843,7	41,195	0	0	0	0	3,00	Nei		Nei	Epidermis mangler	
1F	27. mai 2019	K3	2	354567,74	183,8283333	21	0	21	6	2,00	Antydning		Nei		
1F	27. mai 2019	K3	3	252858,2	149,7283333	19	0	19	4	2,50	Antydning		Nei		
1F	27. mai 2019	K4	1	0	0	0	0	0	0	3,00		1	Nei	Mye bet.eller	
1F	27. mai 2019	K4	2	225032,27	93,53666667	0	0	0	0	2,50	Nei	1		Epidermis mangler litt.	
1F	27. mai 2019	K4	3	326359,26	155,7416667	4	0	4	0	2,00		1			
1F	27. mai 2019	K5	1	222316	169,1566667	0	0	0	0	1,50		1			
1F	27. mai 2019	K5	2	268772,81	138,0033333	5	1	6	0	2,50		1		Flere rare basale celler (se bilde)	
1F	27. mai 2019	K5	3	241850,67	112,41	22	1	23	0	2,50		1			
1F	27. mai 2019	K6	1	198720,41	118,3483333	0	0	0	0	1,50					
1F	27. mai 2019	K6	2	226762,12	101,355	0	0	0	0	2,50	Antydning				
1F	27. mai 2019	K6	3	233865,43	104,3383333	3	0	3	0	2,50				Mye bet.celler.	

Table 8. Histological measurements of Atlantic salmon jaw epidermis from 3dpc-samples, showing the area (um²), thickness (um), number of mucous cells, and morphological score from fish in challenge 2F. The average thickness is based on six measurements. Comments from measurements, and welfare and ulcer score are also included.

Challenge	Date	Sample	Area	Area (um ²)	Avg. thk. (u	Mcuc	MCs	MC tot	MC purple	Epithelium	PP	Bas ept.	Bacteria	Comments	Welfare/ulcer score
2F	20. juni 2019	5b-1	1		#DIV/0!	0	0	0	0	3,00		1			
2F	20. juni 2019	5b-1	2		#DIV/0!	0	0	0	0	1,50		1			
2F	20. juni 2019	5b-1	3		#DIV/0!	0	0	0	0	1,50		1			
2F	20. juni 2019	5b-3	1		#DIV/0!	0	0	0	0	3,00		1			
2F	20. juni 2019	5b-3	2		#DIV/0!	0	0	0	0	2,00		1			
2F	20. juni 2019	5b-3	3		#DIV/0!	0	0	0	0	2,00		1			
														Store deler av epidermis er borte. Har tatt gjennomsnitt av der epidermis er hel.	
2F	20. juni 2019	6b-1	1	58315,6	64,50333333	3	0	3	0	3,00	Ja	1			
2F	20. juni 2019	6b-1	2	217366,58	104,5133333	6	0	6	0	2,50	Ja	1		Vakuolisert	
2F	20. juni 2019	6b-1	3	122983,37	58,80666667	6	0	6	0	2,00	Antydning	1			
2F	20. juni 2019	6b-2	1	113464,89	52,24333333	0	0	0	0	3,00		1		Epidermis er nesten helt borte.	
2F	20. juni 2019	6b-2	2	180090,75	84,54333333	0	0	0	0	3,00		1			
2F	20. juni 2019	6b-2	3	111599,9	54,35833333	1	0	1	0	2,00		1			
2F	20. juni 2019	7b-1	1	455669,16	209,3316667	3	0	3	0	2,00	Antydning.				
2F	20. juni 2019	7b-1	2	290402,79	137,5166667	9	1	10	1	1,50	Antydning				
2F	20. juni 2019	7b-1	3	181565,05	85,12333333	3	0	3	0	1,00	Antydning.				
														Liten del av epidermis er borte.	
2F	20. juni 2019	7b-3	1	258111,25	145,0216667	0	0	0	0	1,50		1			
2F	20. juni 2019	7b-3	2	186662,65	84,44	3	1	4	0	1,50	Antydning	1			
2F	20. juni 2019	7b-3	3	147620,9	63,38833333	10	0	10	2	1,00	Ja	1			
2F	20. juni 2019	K1	1	355236,31	247,2666667	0	0	0	0	1,00	Nei		Nei		
2F	20. juni 2019	K1	2	465626,08	248,4383333	21	0	21	0	1,50					
2F	20. juni 2019	K1	3	241874,81	107,9316667	10	0	10	0	2,00					
2F	20. juni 2019	K2	1	299218,92	169,58	0	0	0	0	2,50	Ja	1		Mye "vakuoler"	
2F	20. juni 2019	K2	2	452380,67	213,0016667	3	0	3	0	2,50	Ja	1			
2F	20. juni 2019	K2	3	132,5666667		0	0	0	0	2,50		1			
														Mye av epidermis er borte fra alle tre områder.	kort snute
2F	20. juni 2019	K3	2		#DIV/0!	0	0	0	0	3,00		1			kort snute
2F	20. juni 2019	K3	3		#DIV/0!	0	0	0	0	3,00		1			kort snute
2F	20. juni 2019	K4	1	251381,86	162,76	0	0	0	0	1,00					
														Rufsete overflate, og basale epitelceller sitter litt "løst"	
2F	20. juni 2019	K4	2	200648,77	99,82833333	4	0	4	0	2,50					
2F	20. juni 2019	K4	3	112246,12	56,105	8	0	8	0	2,50					
														Vakuoler/sitter løst basale epitelceller. Mye betceller i underliggende vev.	
2F	20. juni 2019	K5	1	178560,55	129,9133333	0	0	0	0	1,50		1			
2F	20. juni 2019	K5	2	151072,97	86,795	3	0	3	0	1,00		1			
2F	20. juni 2019	K5	3	128547,85	70,98	1	0	1	0	1,00		1			
														Litt av tuppen er fri for epidermis. Gjennomsnitt av der epidermis er hel.	
2F	20. juni 2019	K6	1	249102,45	122,1816667	0	0	0	0	2,00	Ja, litt.				
2F	20. juni 2019	K6	2	265611,33	140,7483333	0	0	0	0	2,00					
2F	20. juni 2019	K6	3	211926,57	113,2316667	0	0	0	0	2,00				"løse" basale epitelceller	

Table 9. Histological measurements of Atlantic salmon jaw epidermis from 3dpc-samples, showing the area (um2), thickness (um), number of mucous cells, and morphological score from fish in challenge 2LSS. The average thickness is based on six measurements. Comments from measurements, and welfare and ulcer score are also included.

Challenge	Date	Sample	Area	Area (um2)	Avg. thk. (u)	McU	MCs	MC tot	MC purple	Epithelium	PP	Bas ept.	Bacteria	Comments	Welfare/ulcer score
2LSS	20. juni 2019	1b-1	1	92963,25	70,48166667	0	0	0	0	3,00				Epidermis er stygg og mangler i store deler i område 1.	Lite sår. Kort snute
2LSS	20. juni 2019	1b-1	2	150242,85	101,2083333	0	0	0	0	2,00	Ja				Lite sår
2LSS	20. juni 2019	1b-1	3	91368,54	64,12166667	0	0	0	0	1,50	Ja, veldig tydelig.				Lite sår
2LSS	20. juni 2019	1b-2	1	#DIV/0!	0	0	0	0	0					Prøven er snittet rart. Inkluderer ikke denne i resultatene.	Lite sår
2LSS	20. juni 2019	1b-2	2	#DIV/0!	0	0	0	0	0					Prøven er snittet rart. Inkluderer ikke denne i resultatene.	Lite sår
2LSS	20. juni 2019	1b-2	3	#DIV/0!	0	0	0	0	0					Prøven er snittet rart. Inkluderer ikke denne i resultatene.	Lite sår
2LSS	20. juni 2019	2b-2	1	460523,4	289,7733333	0	0	0	0	1,00					
2LSS	20. juni 2019	2b-2	2	479916,51	222,815	2	0	2	0	2,00					
2LSS	20. juni 2019	2b-2	3	165695,15	91,24833333	1	2	3	0	1,50	Ja				
2LSS	20. juni 2019	2b-3	1	277001,92	170,7016667	1	0	1	0	3,00	Ja, antydning i basale celler.			Litt av tuppen er fri for epidermis. Gjennomsnitt av der epidermis er hel.	
2LSS	20. juni 2019	2b-3	2	316028,43	160,4533333	10	0	10	2	1,50	Ja				
2LSS	20. juni 2019	2b-3	3	72531,86	103,8316667	14	0	14	0	1,00					
2LSS	20. juni 2019	3b-1	1	#DIV/0!	0	0	0	0	0			1		Usikker på orientering.	Lite sår
2LSS	20. juni 2019	3b-1	2	#DIV/0!	0	0	0	0	0			1		Usikker på orientering.	Lite sår
2LSS	20. juni 2019	3b-1	3	#DIV/0!	0	0	0	0	0			1		Usikker på orientering.	Lite sår
2LSS	20. juni 2019	3b-2	1	286015,04	173,49	0	0	0	0	1,50	Ja				Sår
2LSS	20. juni 2019	3b-2	2	438649,58	179,5266667	5	1	6	0	1,50	Ja				Sår
2LSS	20. juni 2019	3b-2	3	236720,06	141,74	9	2	11	0	1,00					Sår
2LSS	20. juni 2019	K1	1	394777,46	213,1	0	0	0	0	2,00					kort snute
2LSS	20. juni 2019	K1	2	238264,98	109,0216667	8	0	8	0	2,00					kort snute
2LSS	20. juni 2019	K1	3	202351,18	92,835	7	0	7	0	2,00					kort snute
2LSS	20. juni 2019	K2	1	279788,47	170,435	0	0	0	0	1,50					kort snute
2LSS	20. juni 2019	K2	2	200054,37	97,88666667	0	0	0	0	2,00	Antydning.				kort snute
2LSS	20. juni 2019	K2	3	125338,61	57,59	4	0	4	0	2,00					kort snute
2LSS	20. juni 2019	K3	1	425885,53	175,2716667	1	0	1	0	1,50	Ja				kort snute
2LSS	20. juni 2019	K3	2	309234,64	165,9216667	9	0	9	0	2,00					kort snute
2LSS	20. juni 2019	K3	3	124949,33	77,965	1	0	1	0	1,50	Ja				kort snute
2LSS	20. juni 2019	K4	1	240720,3	202,42	0	0	0	0	1,00					
2LSS	20. juni 2019	K4	2	346562,68	226,9983333	0	0	0	0	1,50					
2LSS	20. juni 2019	K4	3	188234,5	118,305	3	0	3	0	1,50					
2LSS	20. juni 2019	K5	1	#DIV/0!	0	0	0	0	0					Prøven er snittet rart. Inkluderer ikke denne i resultatene.	
2LSS	20. juni 2019	K5	2	#DIV/0!	0	0	0	0	0					Prøven er snittet rart. Inkluderer ikke denne i resultatene.	
2LSS	20. juni 2019	K5	3	#DIV/0!	0	0	0	0	0					Prøven er snittet rart. Inkluderer ikke denne i resultatene.	
2LSS	20. juni 2019	K6	1	246960,71	119,7533333	0	0	0	0	1,50					
2LSS	20. juni 2019	K6	2	206036,96	98,85833333	1	0	1	0	2,00					
2LSS	20. juni 2019	K6	3	117648,53	58,63666667	4	0	4	0	2,00					

Table 10. Histological measurements of Atlantic salmon jaw epidermis from 3dpc-samples, showing the area (um2), thickness (um), number of mucous cells, and morphological score from fish in challenge 3F. The average thickness is based on six measurements. Comments from measurements, and welfare and ulcer score are also included.

Challenge	Date	Sample	Area	Area (um2)	Avg. thk. (µ)	Mcu	MCS	MC tot	MC purple	Epithelium	PP	Bas ept.	Bacteria	Comments	Welfare/ulcer score
3F	15. juli 2019	1c-2	1		#DIV/0!	0	0	0	0	3,00		1	Ja	Epidermis mangler helt i alle tre områder.	Lite sår. snuteskade
3F	15. juli 2019	1c-2	2		#DIV/0!	0	0	0	0	3,00		1	Ja	Epidermis mangler helt i alle tre områder.	Lite sår. snuteskade
3F	15. juli 2019	1c-2	3		#DIV/0!	0	0	0	0	3,00		1		Epidermis mangler helt i alle tre områder.	Lite sår. snuteskade
3F	15. juli 2019	1c-3	1		#DIV/0!	0	0	0	0	3,00		1	Ja?	Epidermis mangler helt i område 1.	Lite sår. snuteskade
3F	15. juli 2019	1c-3	2	291030,71	132,82	2	0	2	0	2,00	Ja	1	Ja		Lite sår. snuteskade
3F	15. juli 2019	1c-3	3	170967,51	94,19333333	4	1	5	0	0,50	Ja	1			Lite sår. snuteskade
3F	15. juli 2019	2c-1	1		#DIV/0!	0	0	0	0	3,00				Epidermis mangler helt i område 1.	Lite sår. snuteskade
3F	15. juli 2019	2c-1	2	463058,99	252,7916667	13	0	13	0	1,00	Ja				Lite sår. snuteskade
3F	15. juli 2019	2c-1	3	316993,56	199,6016667	10	2	12	0	1,50					Lite sår. snuteskade
3F	15. juli 2019	2c-2	1		#DIV/0!	0	0	0	0	3,00				Epidermis mangler helt i område 1.	Lite sår. snuteskade
3F	15. juli 2019	2c-2	2	386688,06	200,4416667	1	0	1	0	1,50	Ja				Lite sår. snuteskade
3F	15. juli 2019	2c-2	3	291244,59	128,935	6	0	6	0	1,50	Ja				Lite sår. snuteskade
3F	15. juli 2019	3c-2	1		#DIV/0!	0	0	0	0	3,00		1	Ja?	Epidermis mangler i område 1.	Sår. snuteskade
3F	15. juli 2019	3c-2	2	323124,62	144,3283333	5	6	11	0	0,50	Ja	1			Sår. snuteskade
3F	15. juli 2019	3c-2	3	326316,08	139,97	26	10	36	0	1,00		1			Sår. snuteskade
3F	15. juli 2019	3c-3	1		#DIV/0!	0	0	0	0	3,00		1	Ja	Epidermis mangler helt i område 1.	Lite sår. snuteskade
3F	15. juli 2019	3c-3	2	137559,32	106,8433333	7	2	9	0	3,00	Ja	1	Ja		Lite sår. snuteskade
3F	15. juli 2019	3c-3	3	166850,41	90,88166667	2	0	2	0	3,00	Ja	1		Epidermis mangler delvis. Har ikke tatt ålinger av der den mangler.	Lite sår. snuteskade
3F	15. juli 2019	K1	1		#DIV/0!	0	0	0	0	3,00		1		Epidermis mangler helt.	
3F	15. juli 2019	K1	2	545812,83	243,0883333	9	0	9	0	1,50		1		Basale epitelceller løsner fra hverandre.	
3F	15. juli 2019	K1	3	394584,91	203,365	32	0	32	0	2,00		1			
3F	15. juli 2019	K2	1	256882,45	172,4266667	0	0	0	0	1,00					
3F	15. juli 2019	K2	2	239247,52	136,06	0	0	0	0	1,50	Antydning.				
3F	15. juli 2019	K2	3	184087,94	100,8116667	1	0	1	0	2,00	Ja				
3F	15. juli 2019	K3	1	240012,36	167,7683333	0	0	0	0	1,50	Antydning				
3F	15. juli 2019	K3	2	141855,24	70,075	0	0	0	0	3,00					
3F	15. juli 2019	K3	3	117762,33	55,23166667	2	0	2	0	2,50					
3F	15. juli 2019	K4	1	195074,39	168,0716667	0	0	0	0	3,00	Ja			Epidermis mangler i deler av område 1.	
3F	15. juli 2019	K4	2	242846,42	137,0616667	4	0	4	0	2,50	Antydning				
3F	15. juli 2019	K4	3	215011,34	122,9383333	15	0	15	0	2,00					
3F	15. juli 2019	K5	1	273821,51	149,165	0	0	0	0	1,50					
3F	15. juli 2019	K5	2	262312,17	127,3783333	2	0	2	0	2,00					
3F	15. juli 2019	K5	3	161309,31	77,26	9	0	9	0	2,00					
3F	15. juli 2019	K6	1		#DIV/0!	0	0	0	0	3,00				Epidermis mangler helt.	
3F	15. juli 2019	K6	2	164619,14	94,51	1	0	1	0	2,00	Ja				
3F	15. juli 2019	K6	3	14239,85	71,38666667	2	0	2	0	2,50	Ja				

Table 11. Histological measurements of Atlantic salmon jaw epidermis from 3dpc-samples, showing the area (um2), thickness (um), number of mucous cells, and morphological score from fish in challenge 3LSS. The average thickness is based on six measurements. Comments from measurements, and welfare and ulcer score are also included.

Challenge	Date	Sample	Area	Area (um2)	Avg. thk. (um)	Mcu	MCs	MC tot	MC purple	Epithelium	PP	Bas ept.	Bacteria	Comments	Welfare/ulcer score
3LSS	15. juli 2019	5c-1	1	385514	200,6683333	0	0	0	0	1,00	Ja	1			Lite sår.
3LSS	15. juli 2019	5c-1	2	284824,59	171,0566667	6	0	6	0	1,00	Ja	1			Lite sår.
3LSS	15. juli 2019	5c-1	3	154889,06	86,72833333	3	0	3	0	2,00		1			Lite sår.
3LSS	15. juli 2019	5c-2	1		#DIV/0!	0	0	0	0	3,00				Epidermis mangler i område 1.	Lite sår. snuteskade
3LSS	15. juli 2019	5c-2	2	405845,44	172,0333333	30	0	30	3	1,50	Ja				Lite sår. snuteskade
3LSS	15. juli 2019	5c-2	3	198900,12	108,8333333	11	0	11	0	1,00	Ja				Lite sår. snuteskade
3LSS	15. juli 2019	6c-1	1		#DIV/0!	0	0	0	0	3,00				Epidermis mangler helt i område 1.	Kort snute
3LSS	15. juli 2019	6c-1	2	201016,08	85,86333333	3	0	3	0	2,00					kort snute
3LSS	15. juli 2019	6c-1	3	109881,36	81,01666667	0	0	0	0	2,00					kort snute
3LSS	15. juli 2019	6c-2	1		#DIV/0!	0	0	0	0	3,00				Epidermis mangler helt i område 1.	Sår.
3LSS	15. juli 2019	6c-2	2	503185,39	243,7533333	0	0	0	0	1,50					Sår.
3LSS	15. juli 2019	6c-2	3	303488,67	176,965	8	0	8	0	2,00					Sår.
3LSS	15. juli 2019	7c-1	1		#DIV/0!	0	0	0	0	3,00					Lite sår. Snuteskade
3LSS	15. juli 2019	7c-1	2	139455,3	66,93833333	3	0	3	0	2,00					Lite sår. Snuteskade
3LSS	15. juli 2019	7c-1	3	130240,1	61,35666667	0	0	0	0	2,50	Ja				Lite sår. Snuteskade
3LSS	15. juli 2019	7c-2	1	224901,2	149,6516667	0	0	0	0	1,00	Ja	1			
3LSS	15. juli 2019	7c-2	2	385444,91	168,4483333	9	0	9	0	1,50		1			
3LSS	15. juli 2019	7c-2	3	191762,27	91,76833333	8	0	8	0	1,50		1			
3LSS	15. juli 2019	K1	1	323359,2	174,9616667	0	0	0	0	1,50	Ja				snuteskade
3LSS	15. juli 2019	K1	2	405392,28	178,1566667	0	0	0	0	2,00					snuteskade
3LSS	15. juli 2019	K1	3	324307,83	158,4566667	8	1	9	0	2,00					snuteskade
3LSS	15. juli 2019	K2	1	130399,12	88,53333333	0	0	0	0	3,00	Ja	1		Mye av epidermis er veldig tynn og skadet.	kort snute
3LSS	15. juli 2019	K2	2	280036,39	123,25	5	0	5	0	2,50	Ja	1			kort snute
3LSS	15. juli 2019	K2	3	130366,1	76,83333333	10	1	11	0	1,50		1			kort snute
3LSS	15. juli 2019	K3	1	251514,46	176,24	0	0	0	0	1,50		1			kort snute
3LSS	15. juli 2019	K3	2	333096,78	149,0883333	3	0	3	0	2,00		1			kort snute
3LSS	15. juli 2019	K3	3	196396,79	103,4	13	0	13	0	2,50	Ja	1			kort snute snuteskade.
3LSS	15. juli 2019	K4	1		#DIV/0!	0	0	0	0	3,00				Epidermis mangler i område 1.	Kort snute snuteskade.
3LSS	15. juli 2019	K4	2	453219,43	201,2916667	0	0	0	0	2,00					Kort snute snuteskade.
3LSS	15. juli 2019	K4	3	443212,72	199,2683333	21	0	21	0	1,00	Ja				Kort snute
3LSS	15. juli 2019	K5	1	366794,04	203,6733333	0	0	0	0	2,00					
3LSS	15. juli 2019	K5	2	513441,03	229,1433333	17	0	17	0	2,00					
3LSS	15. juli 2019	K5	3	255746,87	115,0316667	24	2	26	0	1,50					
3LSS	15. juli 2019	K6	1		#DIV/0!	0	0	0	0	3,00	Ja			Mye av epidermis er tynn og skadet.	
3LSS	15. juli 2019	K6	2	145901,71	68,22	2	0	2	0	3,00	Ja				
3LSS	15. juli 2019	K6	3	132010,6	59,46833333	3	0	3	0	1,50	Ja				

Appendix 5 – Immunohistochemistry

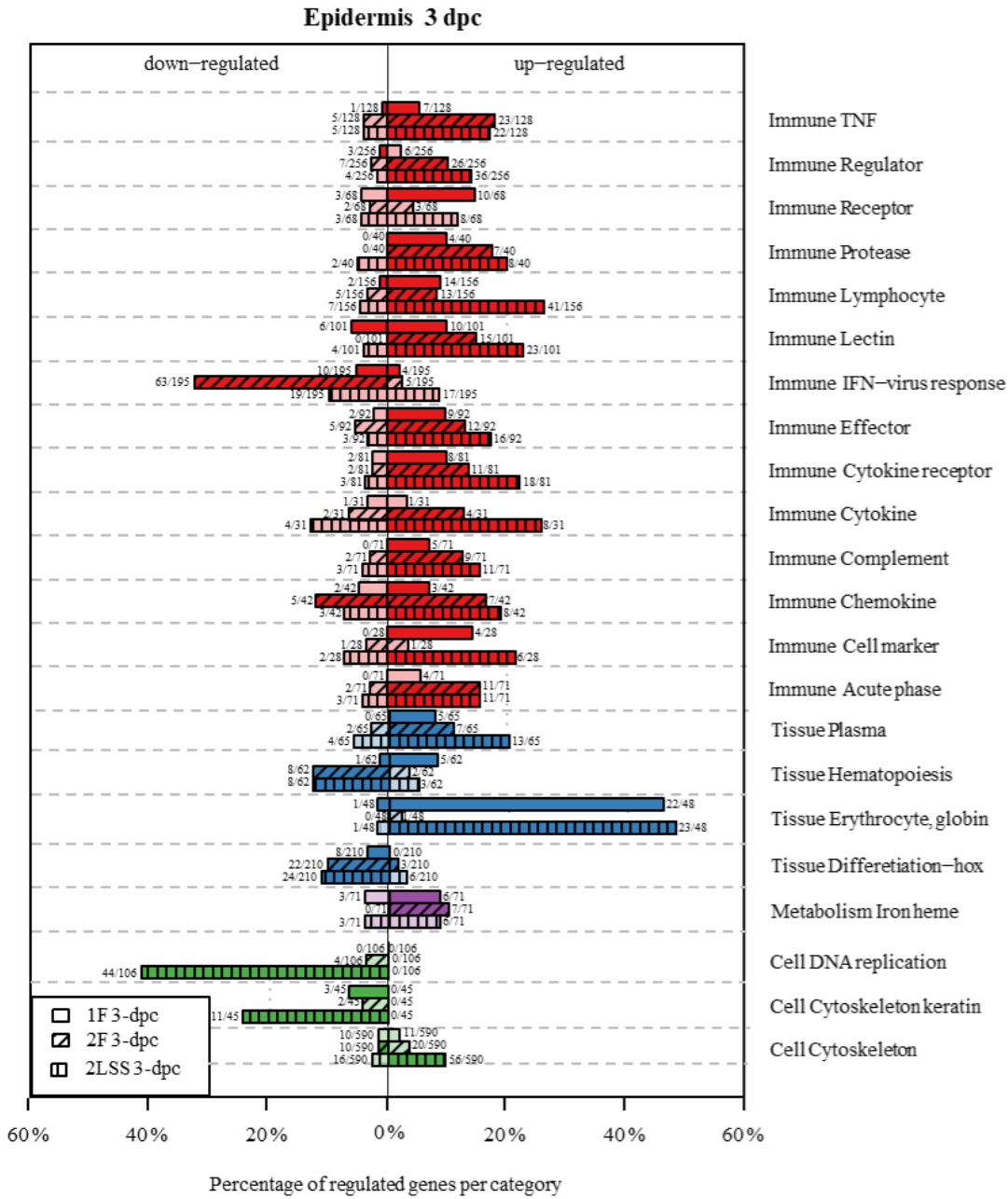
Table 12. Overview of 3 dpc-samples in combination with welfare and ulcer score. Samples for immunohistochemistry are marked either positive (pink) or negative (green) for *T. finnmarkense*.

Challenge	Sample	Welfare/ulcer score		
		Ventral	Jaw	Dorsal
1F	1a-1	gul langs buk		
1F	1a-2		snuteskade	
1F	2a-1			sår, reiste skjell
1F	2a-2			
1F	3a-1			
1F	3a-2			
1F	K1			
1F	K2			
1F	K3			
1F	K4			
1F	K5			
1F	K6			
2F	5b-1	lite sår		
2F	5b-3	sår		
2F	6b-1			
2F	6b-2	sår		
2F	7b-1	påbegynnen de sår		
2F	7b-3	sår. Gul langs buk		
2F	K1			
2F	K2			
2F	K3			
2F	K4			
2F	K5			
2F	K6			
2LSS	1b-1	lite sår	lite sår	
2LSS	1b-2	sår	lite sår	
2LSS	2b-2	sår		
2LSS	2b-3	lite sår		
2LSS	3b-1	sår	lite sår	
2LSS	3b-2		sår	
2LSS	K1			
2LSS	K2			
2LSS	K3			
2LSS	K4			
2LSS	K5			
2LSS	K6			

Challenge	Sample	Welfare/ulcer score		
		Ventral	Jaw	Dorsal
3F	1c-2		lite sår. Snuteskade	
3F	1c-3	påbegynnen de sår buk	lite sår. Snuteskade	
3F	2c-1	gulaktig buk	lite sår. Snuteskade	
3F	2c-2	gulaktig buk	lite sår. Snuteskade	
3F	3c-2		sår. Snuteskade	
3F	3c-3	sår. Gulaktig buk	lite sår. Snuteskade	
3F	K1			
3F	K2			
3F	K3			
3F	K4			
3F	K5			
3F	K6			
3LSS	5c-1		lite sår	
3LSS	5c-2		lite sår. Snuteskade	
3LSS	6c-1			
3LSS	6c-2		sår	
3LSS	7c-1		lite sår. Snuteskade	
3LSS	7c-2			
3LSS	K1		snuteskade	
3LSS	K2			
3LSS	K3			
3LSS	K4		snuteskade	
3LSS	K5			
3LSS	K6			

Appendix 6 – Gene expression

A



B

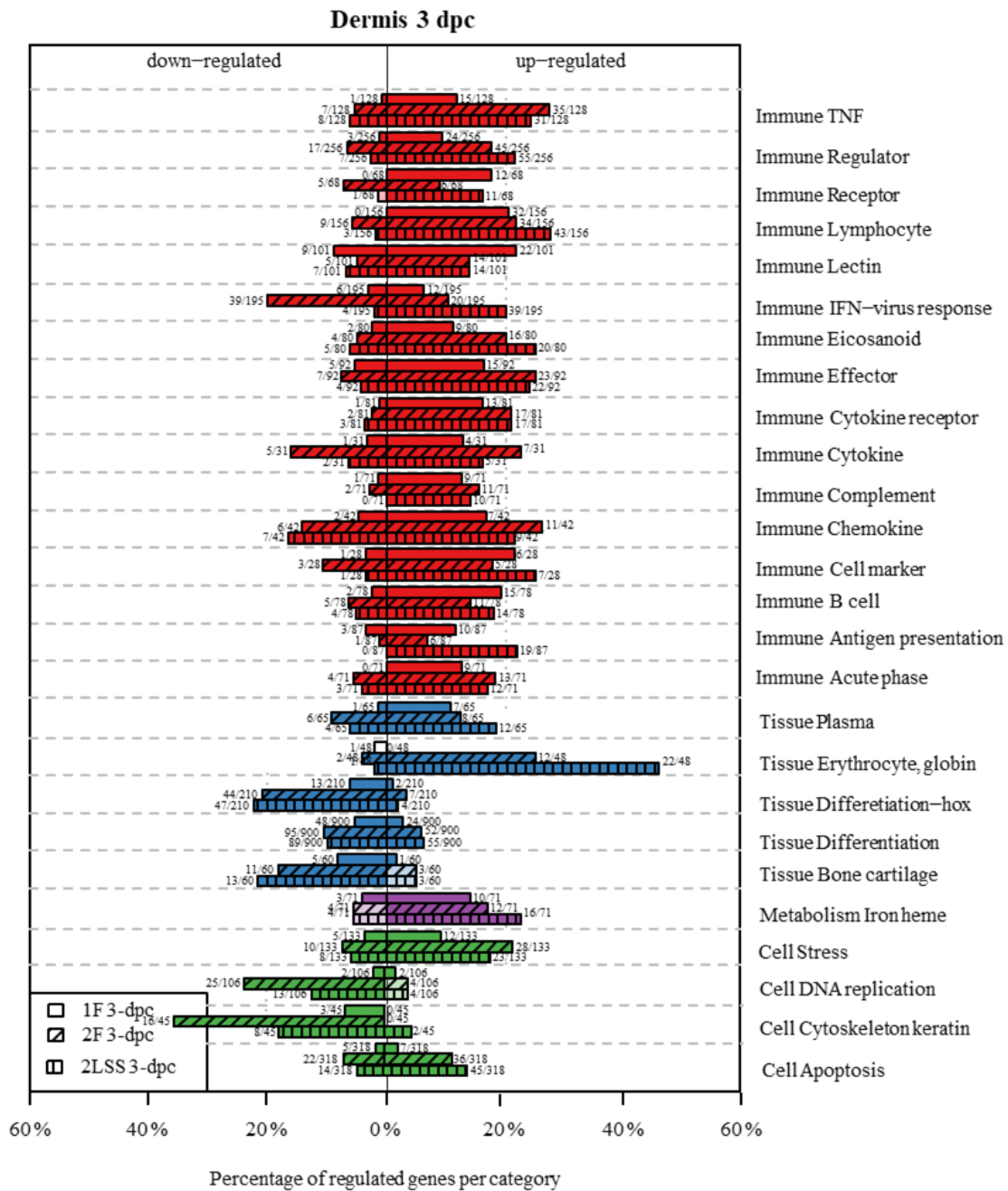


Figure 23. Gene transcription profiling in the epidermis (A) and the dermis (B) layer of Atlantic salmon smolts challenged with *T. finnmarkense*. Differently expressed genes (DEG) shown as down-regulated or up-regulated organized by gene category for 1F, 2F, and 2LSS 3 days post challenge (dpc). Bars represent the percentage of regulated genes per category. The number of DEG vs the number of genes per category is shown for each bar. Dark color versions indicate significant enrichment (Fisher test $p < 0.05$). Light color versions indicate non-significant enrichment. Microarray, statistical analysis, and presentation of data by researchers at Nofima, Ås. Graphs are slightly modified.