

Cardiomyopathy syndrome (CMS) in Atlantic salmon (*Salmo salar* L.), -challenge models and pathogenesis studies

C. Fritsvold*1, M. Alarcón1, R. Johansen1, M. Rode2, P. Nilsen2, R.T. Kongtorp1, O. Breck3, T. Taksdal1 and T.T. Poppe4.

1 National Veterinary Institute, Oslo, Norway, 2 PHARMAQ AS, Oslo, Norway, 3 Marine Harvest Norway AS, Bergen, Norway, 4 Norwegian School of Veterinary Science, 0033 Oslo, Norway

INTRODUCTION & AIM OF STUDY

Cardiomyopathy syndrome (CMS) is a disease of unknown aetiology, having significant economic impact as it primarily affects large farmed Atlantic salmon (*Salmo salar*) in late seawater phase, close to harvest. A low to moderate increase in the mortality rate is often seen for a long period of time and the accumulated mortality may be significant.

In several studies, we have demonstrated that CMS is a transmissible disease under experimental conditions. Histopathological lesions consistent with CMS were induced in Atlantic salmon post-smolts by intraperitoneal injection of either tissue homogenate from farmed fish diagnosed with CMS or material from CMS diseased fish passed in cell culture (cell culture material was provided by PHARMAQ). In this poster, detailed histology results from our latest challenge experiment will be presented.

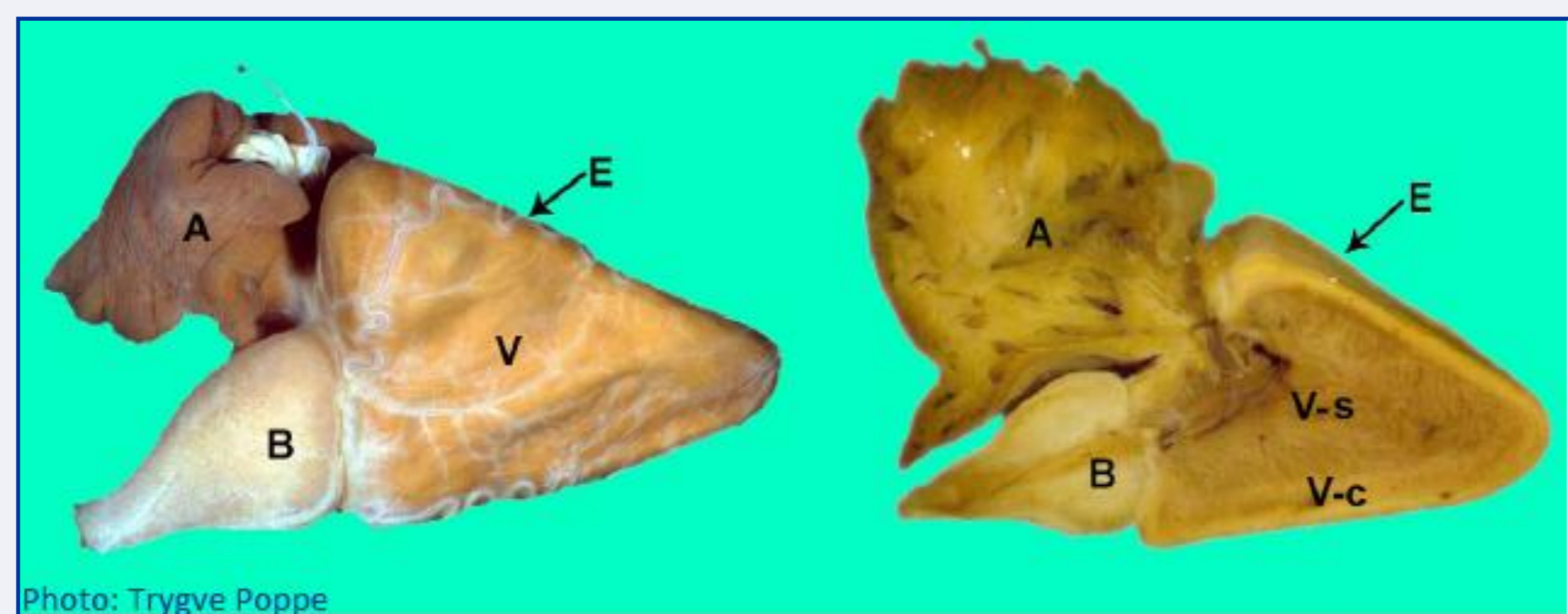


Figure 1: The salmon heart: Heart from wild Atlantic salmon (*Salmo salar*), intact (left) and with a longitudinal section (right). A= Atrium, B= Bulbus arteriosus, V= Ventricle, V-s= Spongy layer of the ventricle, V-c= Compact layer of the ventricle

MATERIALS AND METHODS

Design, experimental fish and sampling

The experiment was conducted in sea water at VESO Vikan research facility (Namsos, Norway), as a clinical study with controls in a parallel group design. Experimental fish were of Aqua Gen origin, each experimental group in a separate tank.

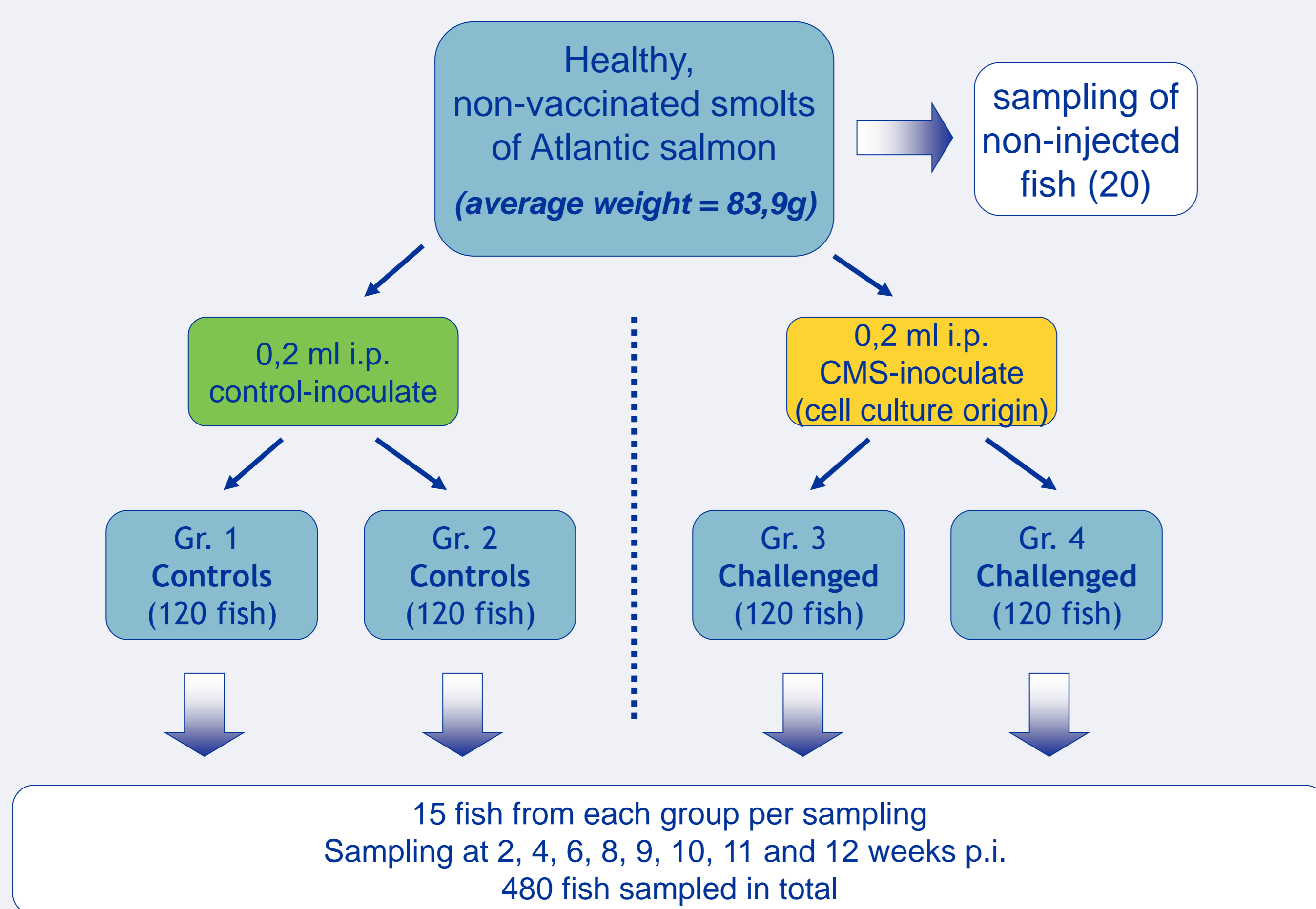


Figure 2: Overview of challenge experiment and samplings

Histopathology

Histological sections of cardiac tissue from 500 fish (H&E staining) were examined and classified based on the presence of mononuclear endo- and myocarditis, degeneration and necrosis in the spongy layer of the ventricle and atrium (Ferguson et al. 1990)¹. The atrium, the epi-cardium, the spongy and compact layers of the ventricle were evaluated separately and graded from 0 to 4 according to the criteria in table 1 (Fritsvold et al. (in press))².

Score	Description
0	No pathological findings, or slightly increased number of leukocytes
1	One or few focal lesions, increased number of leukocytes
2	Several distinct lesions and small to moderate increase in number of leukocytes
3	Multifocal to confluent lesions and moderate to severe increase in number of leukocytes.
4	Severe confluent lesions comprising more than 75% of the tissue and massive leukocyte infiltration

Table 1: Histological classification of lesions in endo-, epi- and/or myocardium

RESULTS

Histopathology

Experimental challenged fish started developing focal to multi-focal lesions in the atrial endo- and myocardium about 6 weeks post injection (+/- 2 weeks), with subsequent progression to the ventricle. This proceeded into severe endocarditis and subsequent myocarditis with mononuclear cell infiltration of the atrium and, to a lesser degree, the spongy layer of the ventricle. No fish had grade 4 lesions in any compartment of the heart in this experiment.

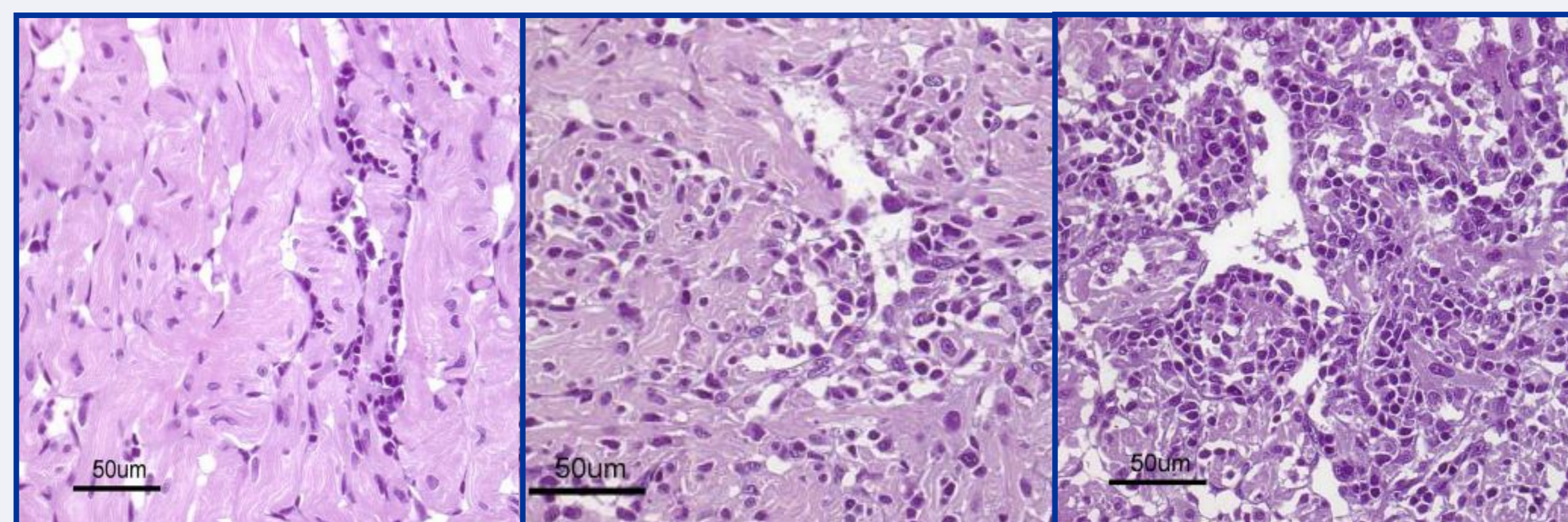


Figure 3. Examples of histological classification (from left to right): Grade 1 (spongy myocardium, ventricle), grade 2 (atrium) and grade 3 (atrium), (H&E-staining)

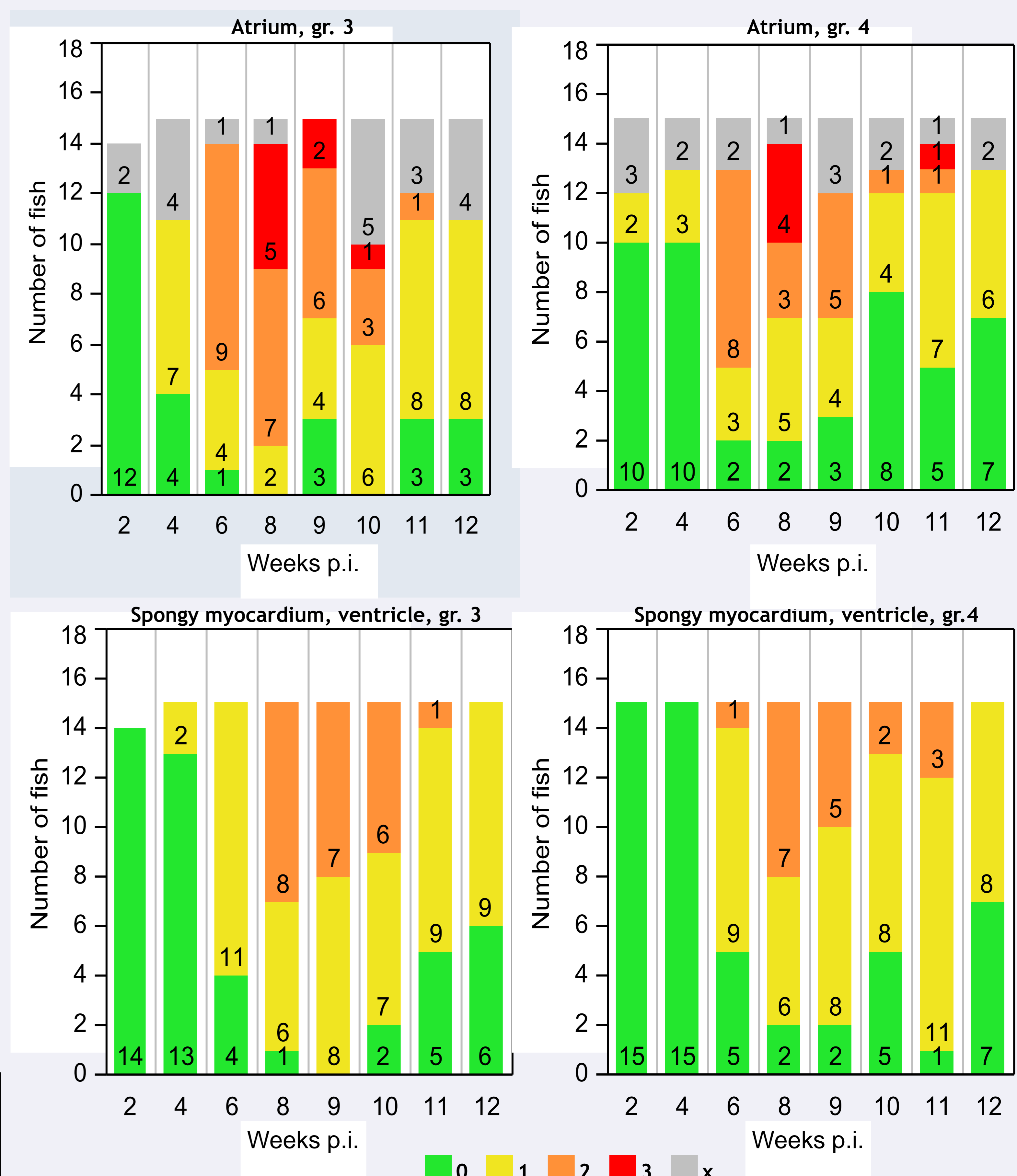


Figure 4: Graphical presentation of CMS lesions in the challenged fish (gr. 3 and 4). Colours represent score level of the CMS lesions, number on columns are the number of fish with lesions of this score. Grey area represent the number of fish with no or too small amount of atrial tissue to evaluate in the histology slide.

CONCLUSION

- The results indicate that CMS has an infectious aetiology and should be treated as a potentially contagious disease.
- The histopathological cardiac changes seen in naturally occurring CMS were reproduced in the challenged fish.
- The established challenge model opens for further investigation of the pathogenesis of CMS, characteristics of the host response, isolation and characteristics of a possible causal agent and for development of disease-specific diagnostic tools.

References

1. Ferguson, H.W., Poppe, T.T. and Speare, D.J (1990) Cardiomyopathy in farmed Norwegian salmon. *Diseases of Aquatic Organisms* 8:225-231
2. Fritsvold, C., Kongtorp, R.T., Taksdal, T., Ørpetveit, I., Heum, M. and Poppe, T.T. (in press) Experimental transmission of cardiomyopathy syndrome (CMS) in Atlantic salmon *Salmo salar* L. (*Diseases of Aquatic Organisms*)

Acknowledgements: The pathological results origin from the project "Cardiomyopathy syndrome: A multitask approach to reduce losses and improve knowledge" (project no. 187 301, 2008-2011) financed by Norwegian Research Council (NRC), Norwegian Fisheries and Aquaculture Research Fund (FHF) and the project partners.