

Melaninmisfarging i muskulatur hos laks



Erling Olaf Koppang
Norges veterinærhøgskole
Oslo

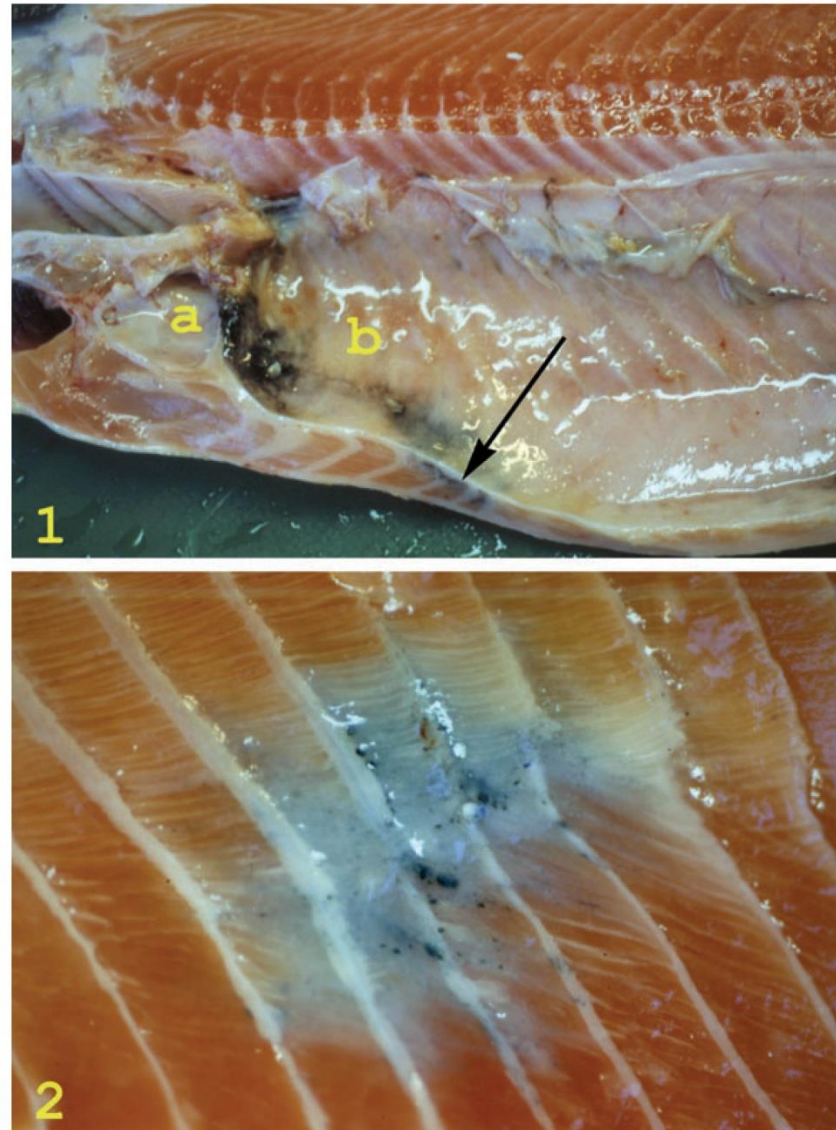
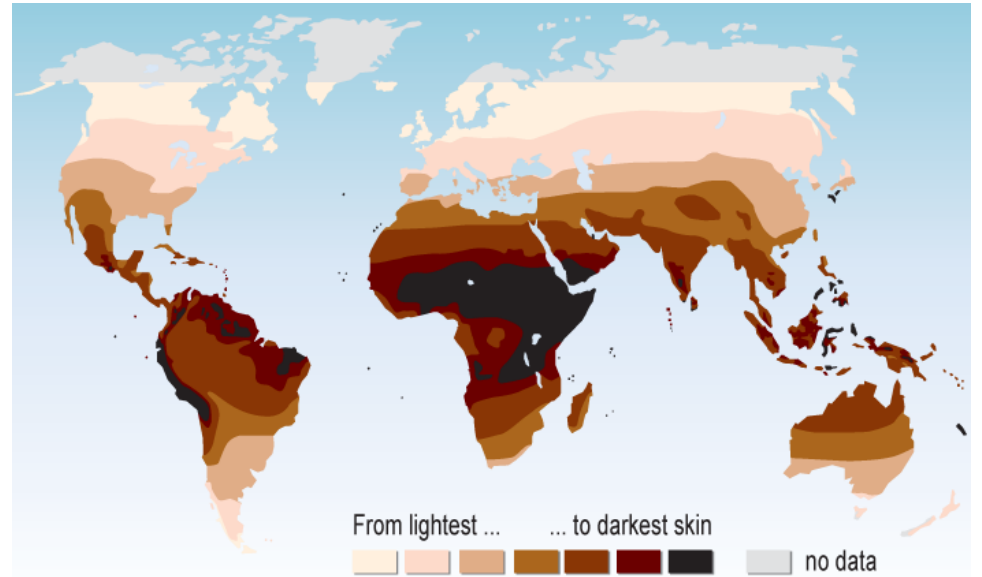
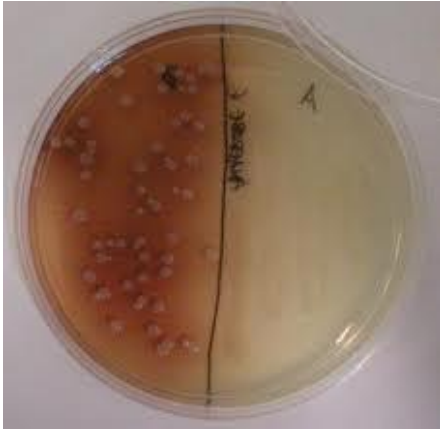


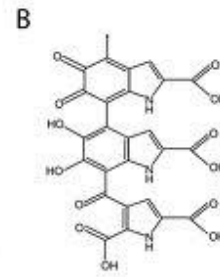
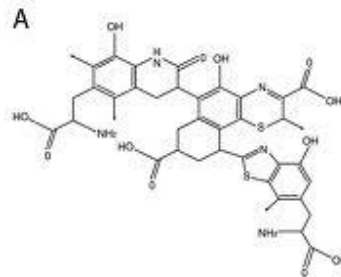
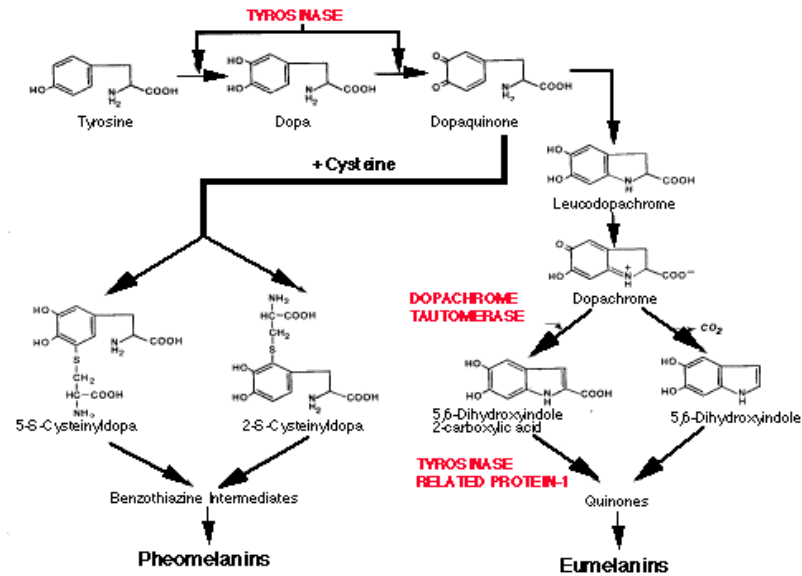
Figure 1 Gross pathological changes in the carcass of an Atlantic salmon. The pericardial cavity (a) is normal, but severe melanization is apparent in the abdominal cavity (b). Melanized musculature subjacent to the peritoneum is seen on the cut surface (arrow).

Figure 2 A melanized area in the musculature of an Atlantic salmon. The peritoneum is removed and darker foci are seen in a dark to grey area involving five myosepta. The lesion is situated laterally in the fish, covering the area of the lateral organ. Note the contraction in the musculature, disrupting the curves of the intramuscular septa.

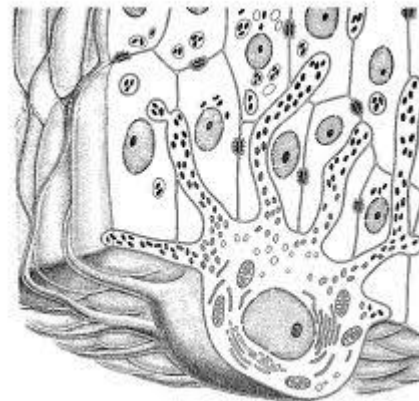
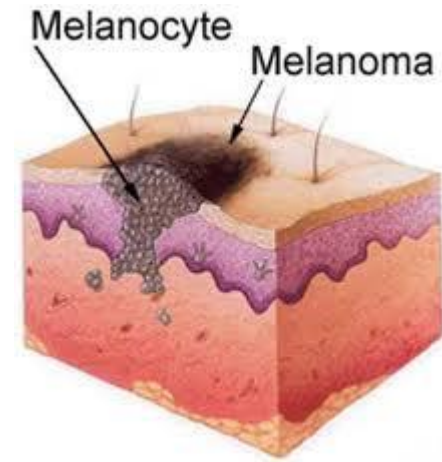
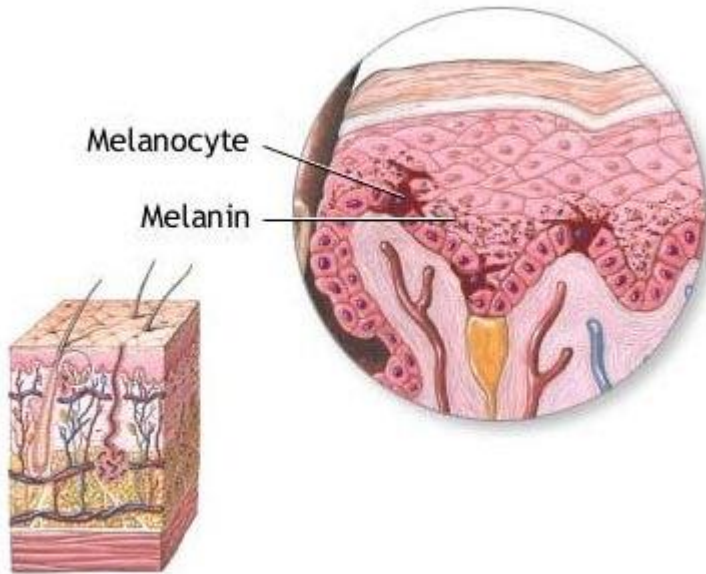


1. Hva er melanin?

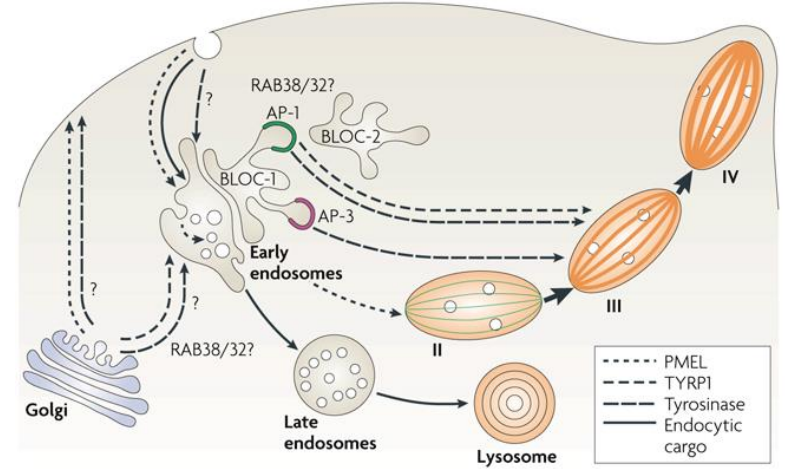
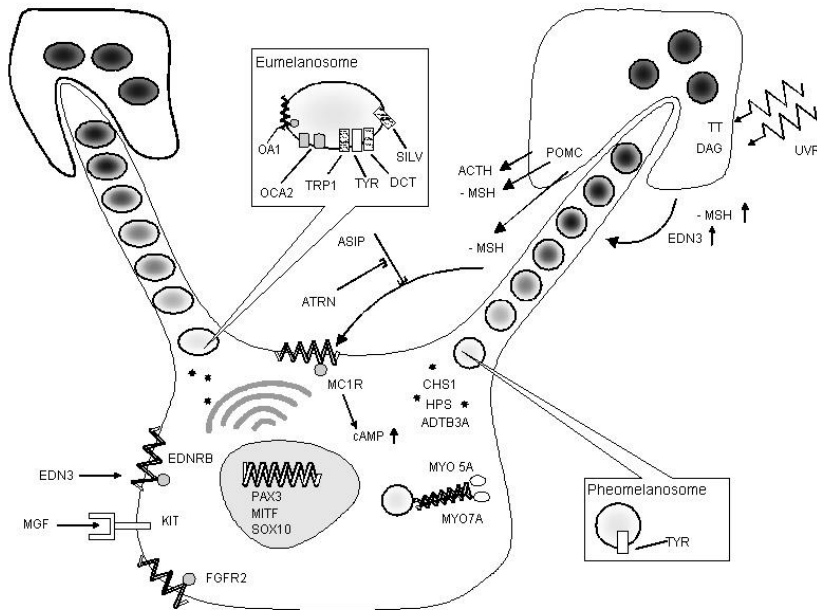
The Melanin Chemical Pathway



Hvor dannes melanin?




Melanosom: den intracelluære melaninfabrikken



- PMEL
- TYRP1
- Tyrosinase
- Endocytic cargo

2. Hvilke funksjoner har melanin?

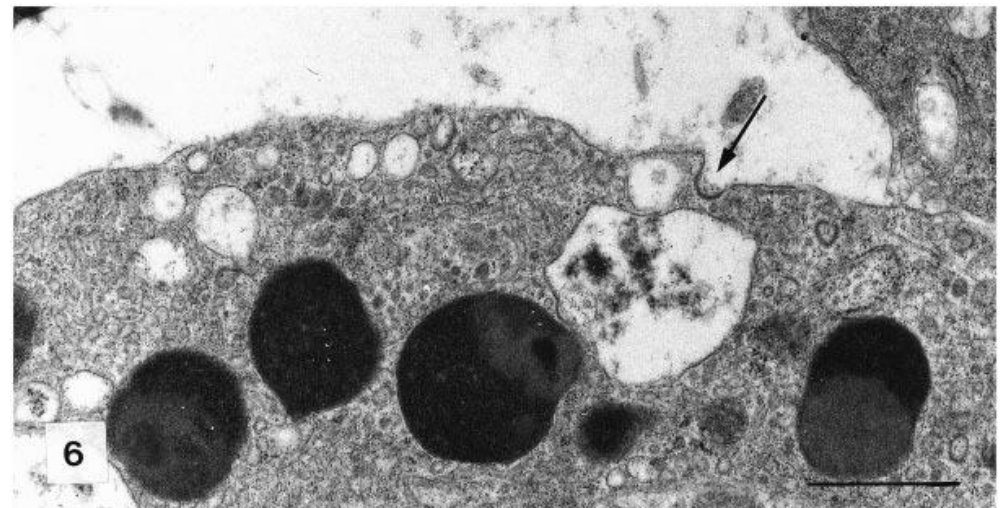
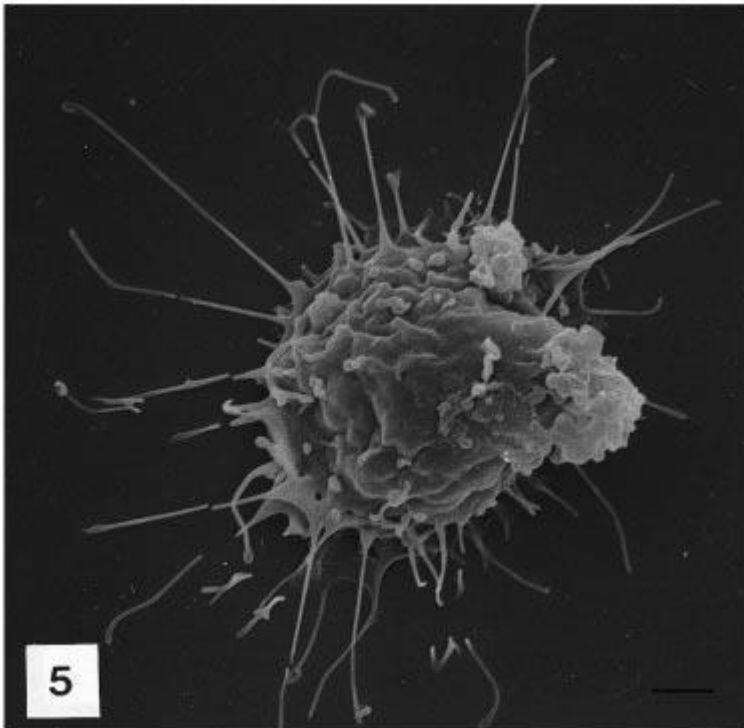
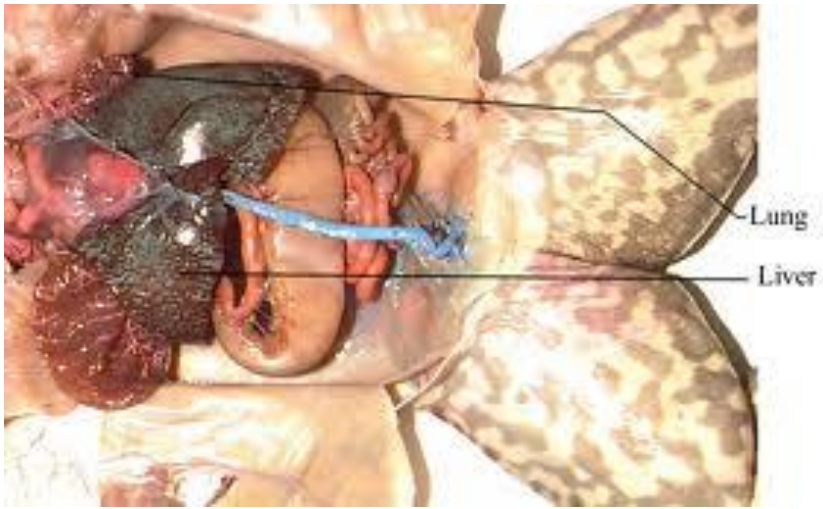






Giovanni Sichel – Universitetet i Catania





Giovanni Sichel og medarbeidere:

- Melaninproduksjon hos virveldyr er ikke utelukkende relatert til celler av ectodermal opprinnelse
- Kupfferske celler i leveren hos amfibier kan lage melanin
- Kupfferske celler er av mesenchymal opprinnelse
- Altså: Populasjoner av forsvarsceller kan lage melanin – ulikt det man ser hos pattedyr

Vaccine-associated granulomatous inflammation and melanin accumulation in Atlantic salmon, *Salmo salar* L., white muscle

E O Koppang¹, E Haugarvoll¹, I Hordvik², L Aune¹ and T T Poppe¹

¹ Department of Basic Sciences and Aquatic Medicine, Norwegian School of Veterinary Science, Oslo, Norway
² Department of Fisheries and Marine Biology, HiB, University of Bergen, Norway

Abstract

The purpose of this study was to investigate the nature of variably sized pigmented foci encountered in fillets of farmed Atlantic salmon, *Salmo salar* L. The material was sampled on the filler production line and on salmon farms from fish with an average size of 3 kg from various producers. The fish had been routinely vaccinated by injection. Gross pathology, histology, immunohistochemistry using antisera against major histocompatibility complex (MHC) class II β chain and transmission electron microscopy (TEM) were used to characterize the changes. Macroscopically, melanized foci were seen penetrating from the peritoneum deep into the abdominal wall, sometimes right through to the skin, and also embedded in the caudal musculature. Histological investigation revealed muscle degeneration and necrosis, fibrosis and granulomatous inflammation containing varying numbers of melano-macrophages. Vacuoles, either empty or containing heterogeneous material, were frequently seen. The presence of abundant MHC class II⁺ cells indicated an active inflammatory condition. TEM showed large extracellular vacuoles and leucocytes containing homogeneous material of lipid-like appearance. The results showed that the melanized foci in Atlantic salmon fillet resulted from an inflammatory condition probably induced by vaccination. The described condition is not known in wild salmon and in farmed salmon where injection vaccination is not applied.

Correspondence: Trygve T Poppe, Department of Basic Sciences and Aquatic Medicine, Norwegian School of Veterinary Science, Ullevålsveien 72, Box 8148 Dep., 0333 Oslo, Norway (e-mail: trygve.poppe@vetinst.no)

Keywords: Atlantic salmon, inflammation, melano-macrophage, major histocompatibility complex class II, mineral oil, vaccine.

Introduction

Various pathological conditions may be associated with abnormal pigmentation in tissues and organs. Such pigments may either be of exogenous or endogenous origin. Endogenous pigments include derivatives of lipids, haemoglobin, porphyrins and melanin. The term melanosis is used to describe the presence of melanin in abnormal locations (Thomson 1984). In vertebrates, melanin is synthesized by melanocytes and organized in melanosomes, which are lysosome-related intracellular organelles (Orlov 1995; Raposo, Favier, Soorvogel & Marks 2002). Mammalian melanocytes originate from the embryonic neural tube (Salmón & Kitchell 2003) and it has been observed that such cells can migrate into inflamed tissue (Thomson 1984).

Inflammatory reactions and tissue regeneration in salmonids seem similar to those of mammals (Finn & Nielson 1971), but have in addition been associated with the involvement of so-called melano-macrophages (Roberts 1975; Agius & Roberts 2003). The origin of melanosomes in melanin-containing viscera located cells in fish is not clear (Agius & Roberts 2003), but Sichel, Scalia, Mondio & Corsaro (1997) suggested that melanogenesis in poikilothermic vertebrates may occur in mesenchyme-derived cells of the haematopoietic lineage. Although teleost melano-macrophages have been ascribed macrophage-like properties, their functions and significance are

Journal of Fish Diseases 2005, 28, 13–22

E O Koppang et al. Vaccine-associated pathology in salmon muscle

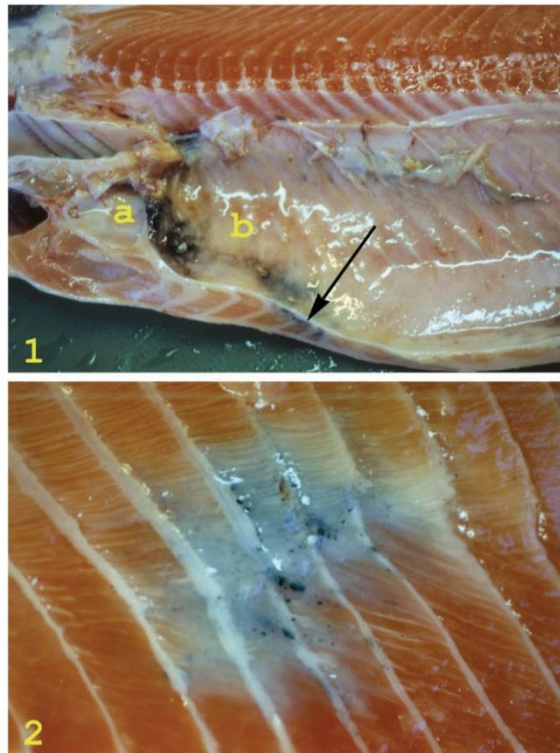


Figure 1 Gross pathological changes in the carcass of an Atlantic salmon. The pericardial cavity (a) is normal, but severe melanization is apparent in the abdominal cavity (b). Melanized musculature subjacent to the peritoneum is seen on the cut surface (arrow).

Figure 2 A melanized area in the musculature of an Atlantic salmon. The peritoneum is removed and darker foci are seen in a dark to grey area involving five myosepta. The lesion is situated laterally in the fish, covering the area of the lateral organ. Note the contraction in the musculature, disrupting the curves of the intramuscular septa.

Journal of Fish Diseases 2005, 28, 13–22

E O Koppang et al. Vaccine-associated pathology in salmon muscle

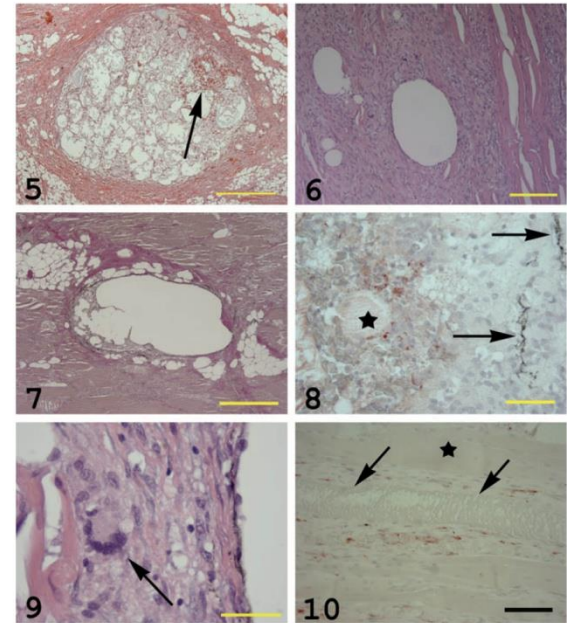


Figure 5 A large vesicle embedded in an intermyotomal septum containing macrophage-like cells, debris and a fresh haemorrhage (arrow) (H&E, bar = 500 μ m).

Figure 6 Empty vesicles surrounded by granulomatous tissue embedded in the white musculature. Note adjacent, seemingly unaffected muscle cells (H&E, bar = 200 μ m).

Figure 7 Vesicles embedded in the white musculature surrounded by fibrogranulomatous tissue (red staining) (EVG, bar = 500 μ m).

Figure 8 Reaction against oil (red staining) in a vesicle as shown in Fig. 5. Homogeneous masses (asterisk) and macrophage-like cells show positive reactions. Note the melano-macrophages in the vesicle wall (arrows) (oil red O, bar = 50 μ m).

Figure 9 High magnification of the wall of a vesicle as seen in Fig. 6. The wall contains a multinucleated giant cell (MGC) (arrow), epithelioid-like cells, small vacuoles and is lined towards the lumen of the greater vesicle with melanosome-containing cells, probably swollen melano-macrophages (H&E, bar = 40 μ m).

Figure 10 Muscle cells infiltrated with MHC class II⁺ cells. One muscle cell is unaffected (asterisk). One fibre shows severe degeneration (arrowhead), whereas one is invaded by MHC class II⁺ cells (red reaction) (MHC class II immunostain, haematoxylin counterstain, bar = 100 μ m).

Melanogenesis and evidence for melanosome transport to the plasma membrane in a CD83⁺ teleost leukocyte cell line

Erlend Haugarvoll^{1*}, Jim Thorsen¹, Morten Laane², Qirong Huang¹ and Erling Olaf Koppang¹

¹Institute of Basic Sciences and Aquatic Medicine, Norwegian School of Veterinary Science, Ullevålsveien 72, PO Box 8146 Dep., 0033 Oslo, Norway

²Institute of Molecular Bioscience, University of Oslo, 0316 Oslo, Norway

*Address correspondence to Erlend Haugarvoll, e-mail: erlend.haugarvoll@veths.no

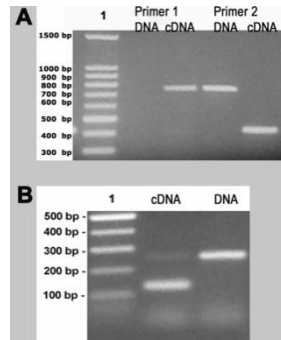
Key words: CD83/dendritic cell/endosomal pathway/macrophage/melanogenesis/melanomacrophage/teleost

Received 1 April 2005, revised and accepted for publication 14 December 2005

Introduction

Melanins are complex polymeric pigments, which are formed by a wide variety of living organisms ranging from fungi and bacteria to higher vertebrates (Margalith, 1992; Orlov, 1995; Raposo et al., 2002). Common for

Summary

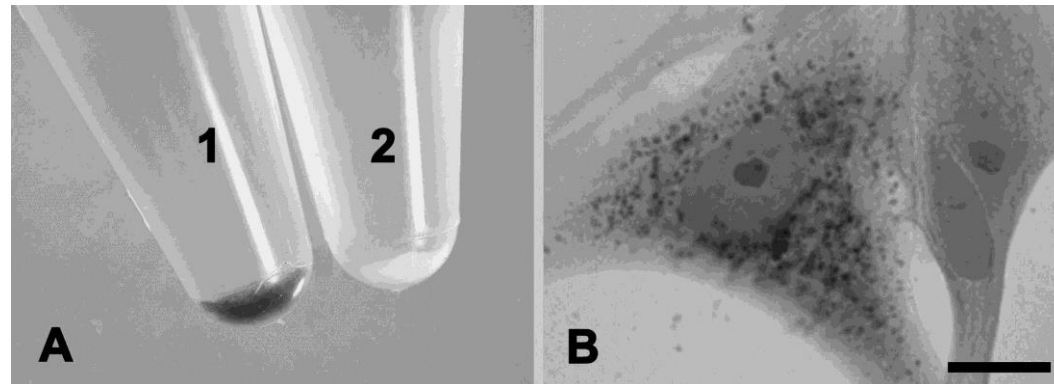


- Primer pairs recognising a fish CD83 homolog

- Primer pair detecting Dct/TRP-2

- A; 0,1 mM PTU inhibit tyrosinase dopachrome production from L-DOPA

- B; a few long cultured cells showed melanin reduction potential



[Biochem Cell Biol.](#) 2012 Dec;90(6):769-78. doi: 10.1139/o2012-033. Epub 2012 Nov 20.

Melanogenesis in visceral tissues of *Salmo salar*. A link between immunity and pigment production?

[Arciuli M](#), [Fiocco D](#), [Cicero R](#), [Maida I](#), [Zanna PT](#), [Guida G](#), [Horsberg TE](#), [Koppang EO](#), [Gallone A](#).

Source

Sezione di Biologia Medica, Dipartimento di Scienze Mediche di Base, Neuroscienze ed Organi di Senso, Università degli Studi di Bari, Policlinico-Piazza Giulio Cesare, 70124 Bari, Italy.



Contents lists available at SciVerse ScienceDirect

Fish & Shellfish Immunology

journal homepage: www.elsevier.com/locate/fsi



Pigment-producing granulomatous myopathy in Atlantic salmon: A novel inflammatory response

Hilde A.S. Larsen^a, Lars Austbø^b, Turid Mørkøre^c, Jim Thorsen^d, Ivar Hordvik^e, Uwe Fischer^f, Emilio Jirillo^g, Espen Rimstad^h, Erling O. Koppang^{a,*}

^a Section of Anatomy and Pathology, Institute of Basic Science and Aquatic Medicine, Norwegian School of Veterinary Science, Ullevålsveien 72, PO Box 8146 Dep., 0033 Oslo, Norway

^b Section of Genetics, Department of Basic Science and Aquatic Medicine, Norwegian School of Veterinary Science, Oslo, Norway

^c Nofima Marin AS, Ås, Norway

^d Section of Cancer Cytogenetics, Institute for Medical Informatics, Oslo University Hospital HF, Oslo, Norway

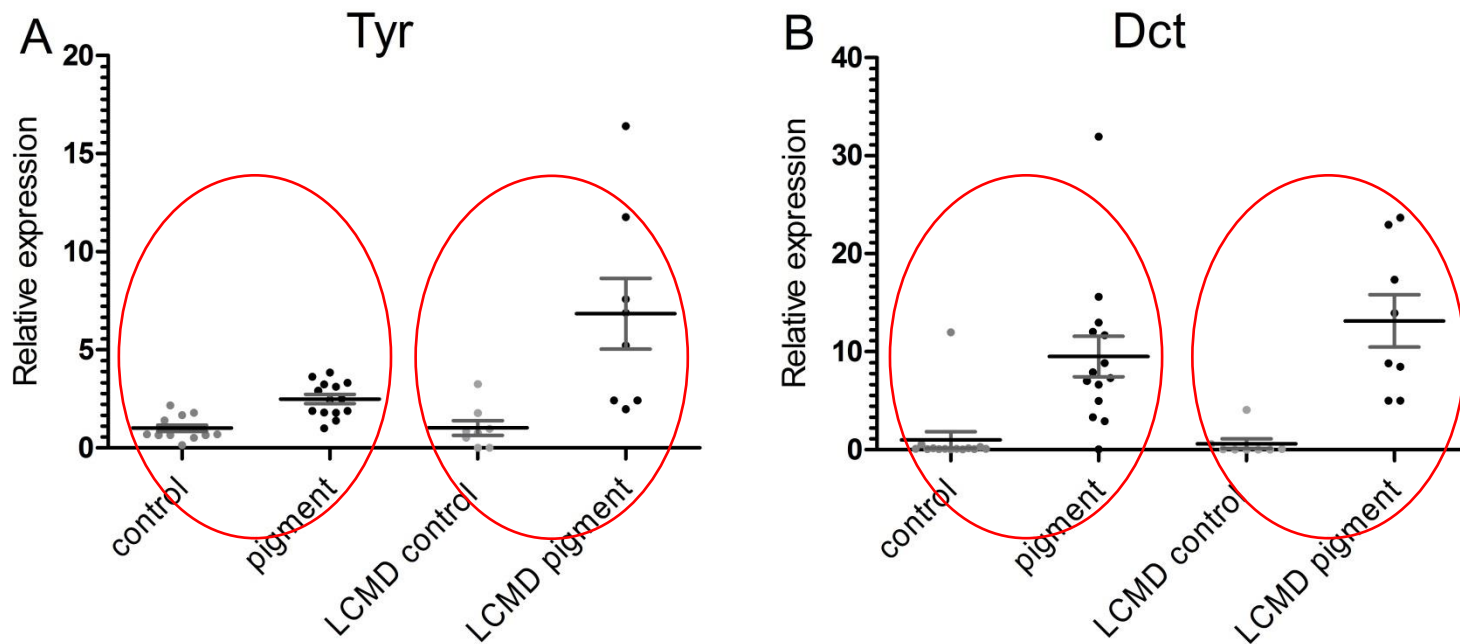
^e Department of Biology, University of Bergen, Bergen, Norway

^f Friedrich-Loeffler-Institut, Federal Research Institute for Animal Health, Institute of Infectology, Greifswald-Insel Riems, Germany

^g Department of Immunology, Faculty of Medicine, University of Bari, Bari, Italy

^h Section of Microbiology, Immunology and Parasitology, Department of Food Safety and Infection Biology, Norwegian School of Veterinary Science, Oslo, Norway

Up-regulation of the tyrosinase gene family in the black spots



The effect of vaccination, ploidy and smolt production regime on pathological melanin depositions in muscle tissue of Atlantic salmon, *Salmo salar* L.

H A S Larsen¹, L Austbø², A Nødtvedt³, T W K Fraser³, E Rimstad⁴, P G Fjellidal⁵, T Hansen⁵ and E O Koppang¹

1 Department of Basic Science and Aquatic Medicine, Section of Anatomy and Pathology, Norwegian School of Veterinary Science, Oslo, Norway

2 Department of Basic Science and Aquatic Medicine, Section of Genetics, Norwegian School of Veterinary Science, Oslo, Norway

3 Department of Production Animal Clinical Sciences, Norwegian School of Veterinary Science, Oslo, Norway

4 Department of Food Safety and Infection Biology, Section of Microbiology, Immunology and Parasitology, Norwegian School of Veterinary Science, Oslo, Norway

5 Institute of Marine Research, Matre Research Station, Matredal, Norway





Contents lists available at SciVerse ScienceDirect

Developmental and Comparative Immunology

journal homepage: www.elsevier.com/locate/dci



Transcription of the tyrosinase gene family in an Atlantic salmon leukocyte cell line (SHK-1) is influenced by temperature, but not by virus infection or bacterin stimulation



Hilde A.S. Larsen^a, Lars Austbø^b, Melanie König^b, Henning Sørum^c, Espen Rimstad^c, Erling O. Koppang^{a,*}

^aSection of Anatomy and Pathology, Department of Basic Science and Aquatic Medicine, Norwegian School of Veterinary Science, Oslo, Norway

^bSection of Genetics, Department of Basic Science and Aquatic Medicine, Norwegian School of Veterinary Science, Oslo, Norway

^cSection of Microbiology, Immunology and Parasitology, Department of Food Safety and Infection Biology, Norwegian School of Veterinary Science, Oslo, Norway


Pathological pigmentation in the hearts of Atlantic salmon (*Salmo salar* L.) with cardiomyopathy syndrome

Hilde A. S. Fagerland¹, Lars Austbø², Camilla Fritsvold³, Marta Alarcon³, Espen Rimstad⁴, Knut Falk³,

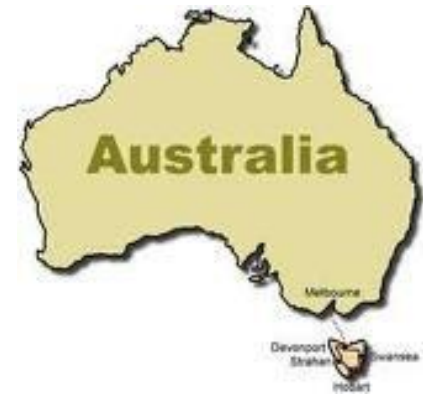Torunn Taksdal³ and Erling O. Koppang^{1,5}

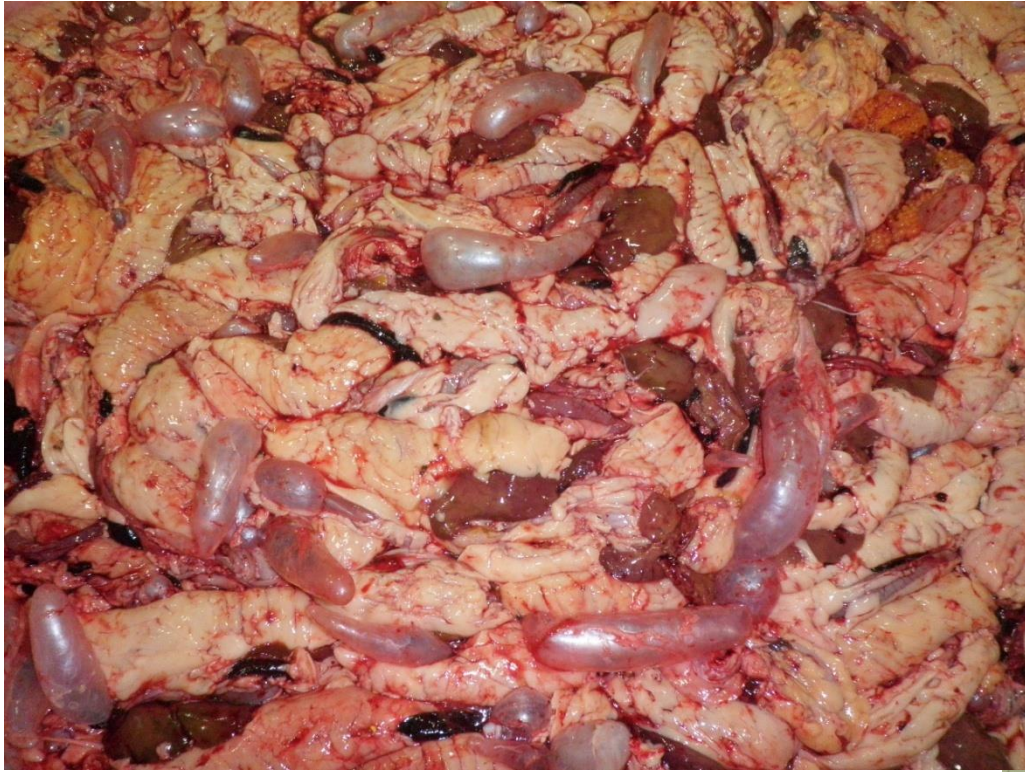¹Section of Anatomy and Pathology, Department of Basic Science and Aquatic Medicine, Norwegian School of Veterinary Science, Oslo, Norway. ²Section of Genetics, Department of Basic Science and Aquatic Medicine, Norwegian School of Veterinary Science, Oslo, Norway. ³ Norwegian Veterinary Institute, Oslo Norway. ⁴Section of Microbiology, Immunology and Parasitology, Department Food Safety and Infection Biology, Norwegian School of Veterinary Science, Oslo, Norway.

Er melanin alltid melanin?









8. Kan melanisering
unngås?
Ja, tydeligvis!

